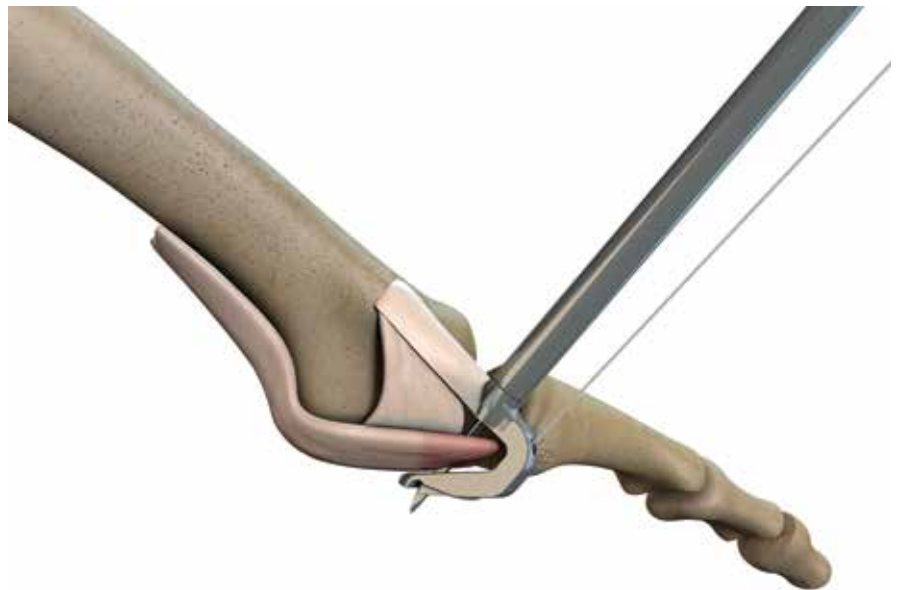


Foot and Ankle Technique Guide  
**Metatarsophalangeal (MTP) Unilateral Joint Repair**



Prepared in consultation with:  
**Phinit Phisitkul, MD**  
Department of Orthopedics and Rehabilitation  
University of Iowa  
Iowa City, IA

# HAT-TRICK<sup>◇</sup> Lesser Toe Repair System

## MTP Unilateral Joint Repair Surgical Technique

The following technique guide contains a summary of medical techniques and opinions based upon the training and expertise of the surgeon advisory team, along with its knowledge of the Smith & Nephew HAT-TRICK Lesser Toe Repair System. Smith & Nephew does not provide medical advice and recommends that surgeons exercise their own professional judgment when determining a patient's course of treatment. This guide is presented for educational purposes only.

### **HAT-TRICK Orthopaedic Advisory Team**

Ned Amendola, MD  
Florian Nickisch, MD  
Phinit Phisitkul, MD  
Charles Saltzman, MD

### **HAT-TRICK Podiatric Advisory Team**

Emily Cook, DPM  
Jeremy Cook, DPM  
David Edwards, DPM  
Mickey Stapp, DPM

## Table of contents

<b>Introduction</b> .....	3
<b>Position the patient</b> .....	4
<b>MTP Unilateral Joint Repair Technique</b> .....	4
Expose the joint and prepare for the repair.....	4
Place the sutures in the plantar plate and collateral ligaments.....	7
Drill the bone tunnel using the Phalangeal Drill Guide.....	11
Complete the repair.....	15
Postoperative care.....	18
<b>Ordering information</b> .....	19

# Introduction

The HAT-TRICK<sup>®</sup> Lesser Toe Repair System is a three-part solution to lesser toe injuries:

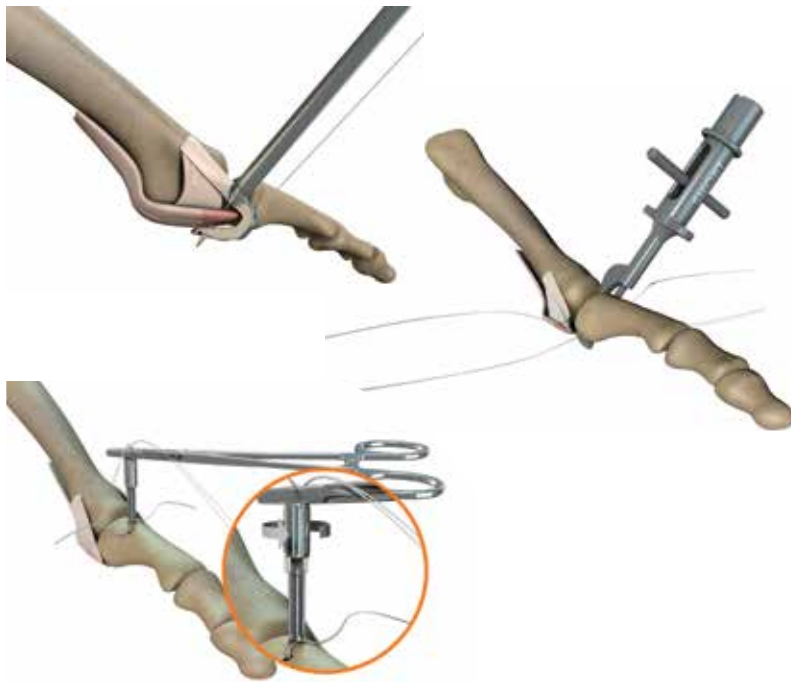
- The HAT-TRICK MTP Joint Repair System (Unilateral and Bilateral)
- The HAT-TRICK Osteotomy Guide for metatarsal shortening procedures
- The HAT-TRICK PIP Fusion System

This technique guide provides a description of the procedure for the HAT-TRICK MTP Unilateral Joint Repair. For information about additional lesser toe repair solutions using the HAT-TRICK Lesser Toe Repair System, please refer to those specific techniques.

## HAT-TRICK MTP Unilateral Joint Repair System

Flexor tendon transfers and Weil osteotomies often lead to loss of ROM, stiffness and residual pain.<sup>1,2,3,4</sup> The HAT-TRICK MTP Unilateral Joint Repair System provides a complete repair of the lesser MTP joint that is less invasive and more anatomic than standard of care techniques. Benefits of the HAT-TRICK System include:

- Anatomic reattachment of collateral ligaments
- Anatomic distal reattachment of the plantar plate
- Preservation of the biomechanical axis, which can be lost when performing a metatarsal osteotomy
- Elimination of the need to release the plantar plate from the metatarsus
- Controlled tensioning of collateral ligaments and plantar plate



The HAT-TRICK MTP Joint Repair System consists of individual single-use disposable procedure packs for both unilateral or bilateral ligament repair, and a sterilization tray with reusable instruments.

Information regarding the instruments used in each procedure can be found in the “Ordering Information” section at the end of this document.

# Position the patient

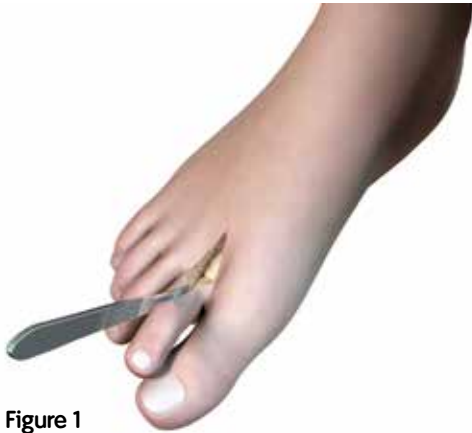1. Place the patient in the supine position with a thigh tourniquet and the foot at the end of the bed.
2. Place a sterile bump underneath the knee of the operative leg so that the foot is in plantar flexion, almost parallel to the ground.

## MTP Unilateral Joint Repair Technique

*Prior to performing this technique, consult the Instructions for Use documentation provided with each device – including indications, contraindications, warnings, cautions and instructions.*

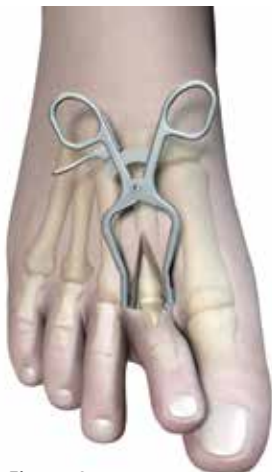### Expose the joint and prepare for the repair

1. Create a longitudinal curvilinear skin incision from the mid-metatarsal to the mid-proximal phalanx while protecting the digital nerve branches. Ensure that the Extensor Digitorum Longus (EDL) Tendon is not damaged during the procedure.
2. Release the extensor hood longitudinally on the side of collateral ligament attenuation to expose the metatarsophalangeal (MTP) joint capsule (Figure 1).



**Figure 1**

3. If necessary, retract the tissue to expose the site using the Trigger Retractor (REF 72204348) (Figure 2).



**Figure 2**

4. Dissect into the extra-articular recess adjacent to the attenuated collateral ligament, down to the level of the deep transverse intermetatarsal ligament. If needed, place a small laminar spreader between the metatarsal necks to increase the working space.
5. Distract the MTP joint using the Small Joint Pin Distractor (REF 72204347) and 1.6mm or 1.1mm K-wires on both sides, approximately 1cm from the joint (Figure 3).

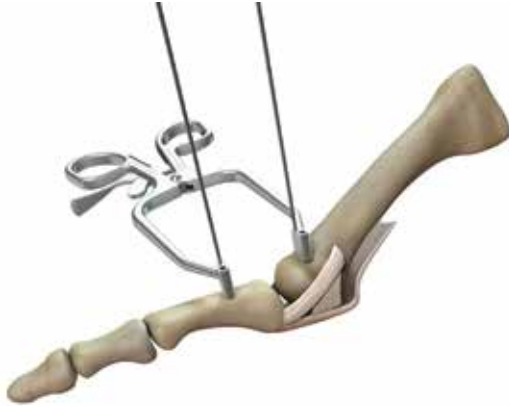

Figure 3

6. Under tension, dissect the collateral ligament (Figure 4) and approximately 50% of the plantar plate ligament (Figure 5) using a #15 blade precisely at the level of the metatarsal head. Ensure that the Flexor Digitorum Longus Tendon (FDL) is not damaged during the dissection.

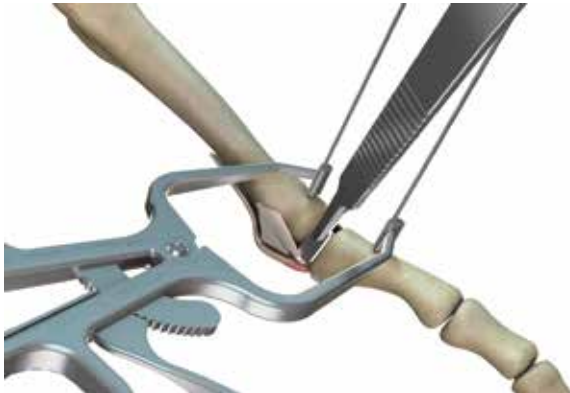

Figure 4




Figure 5

7. Remove the residual parts of the collateral ligament and the plantar plate on the base of the proximal phalanx using rongeurs and a curved blade.
8. To promote healing, denude the ligament insertion sites using the Double Ended Rasp (REF 72204349) (Figure 6).

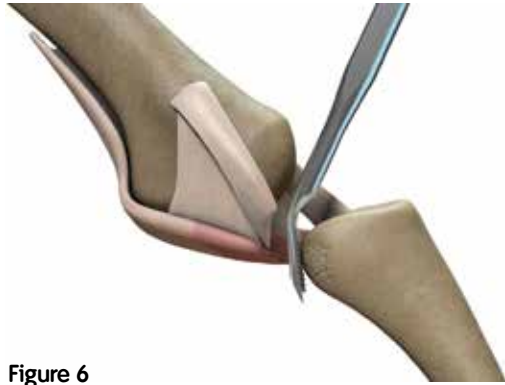


Figure 6

## Place the sutures in the plantar plate and collateral ligaments

1. Identify the FDL tunnel just underneath the plantar plate using the probe side of the Cottle Elevator (REF 72204346).
2. Place the HAT-TRICK® DART Suture Passer Needle into the DART Suture Passer (REF 72204320) by depressing the button on suture passer. Ensure that the bottom of the "I" mark on the needle aligns with the top of the suture passer (Figures 7a and 7b).

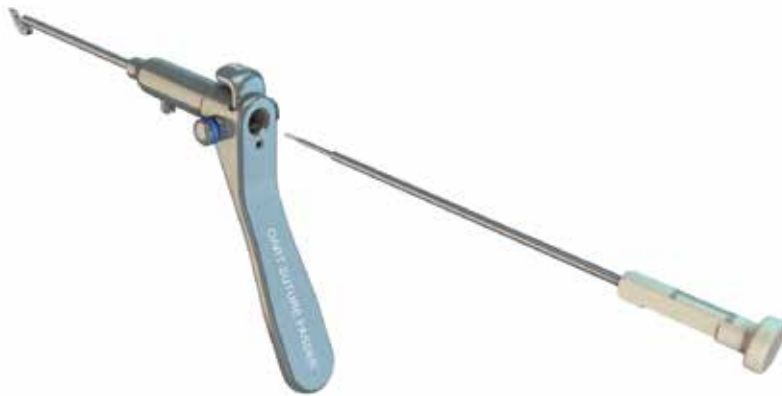

Figure 7a




Figure 7b

3. Load the 2-0 ULTRABRAID<sup>®</sup> Suture from the procedure pack onto the DART Suture Passer (Figure 8).



Figure 8

4. Wind the suture around one of the suture passer posts. Ensure that the suture is taut (Figure 9).

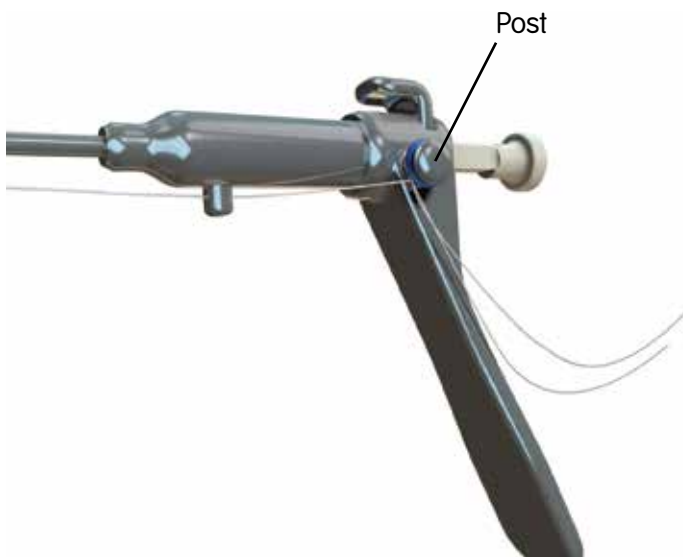


Figure 9



5. Place the suture passer tip into the FDL tunnel and advance the tip as proximally as possible to obtain the maximal hold on the plantar plate (Figure 11). A Cottle Elevator can be placed just dorsal to the plantar plate to provide clearance from the metatarsal head.
6. Hold the DART Suture Passer in place, fully depress the spring-loaded needle, and slowly release the needle to engage the suture (Figure 10).

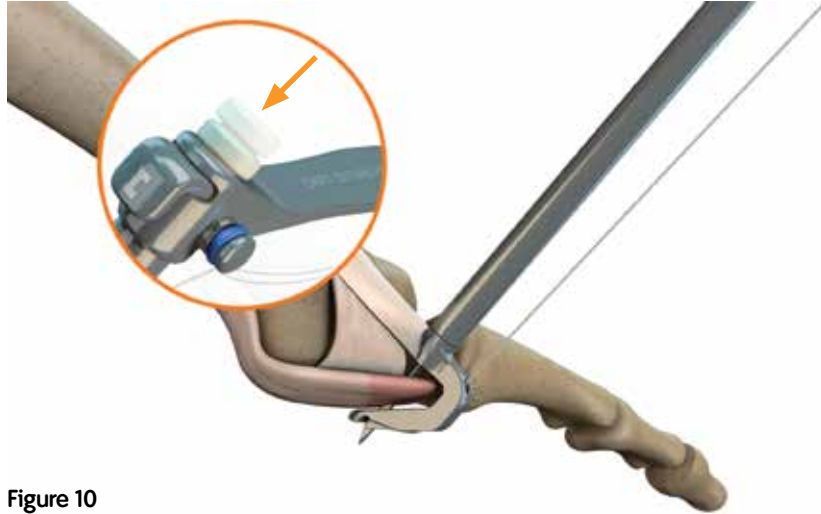


Figure 10

7. Unwind the suture from the suture passer post. This will allow the needle to retract while retrieving a suture loop.
8. Retract the suture passer and needle assembly from the surgical site with a gentle rocking motion to expose the suture loops.

**Note:** Do not remove the needle from the suture passer at this time.

9. Slightly depress the needle to release the suture loop from the needle tip. Grasp the loop of the suture and remove the suture passer/needle assembly from the joint space (Figure 11).

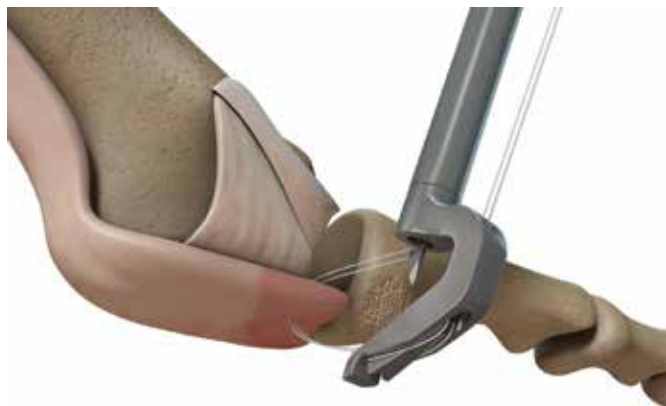
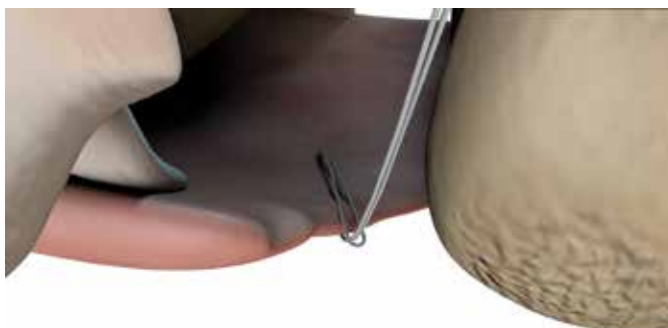
Figure 11: Release the suture from the DART Suture Passer

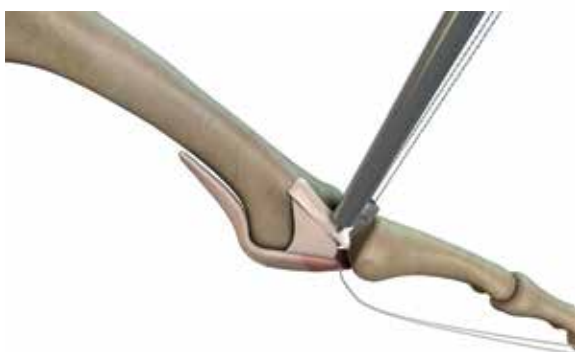
10. Pass the free ends of the suture through the loop to create a double girth stitch (Figure 12).



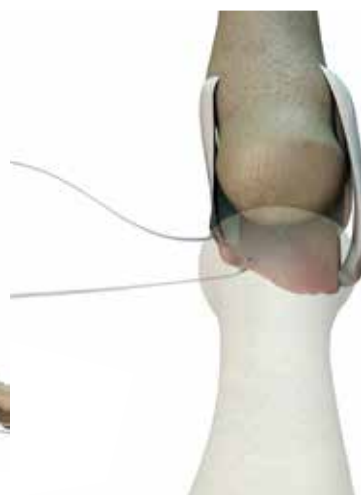**Figure 12: Completed double girth stitch**

11. Identify the collateral ligament and insert the prong of the DART Suture Passer intra-articularly into the gutter of the joint. Then aim the suture passer outward toward the proximal aspect of the collateral ligament.
12. Repeat steps 2–10 with the second, different colored, ULTRABRAID® 2-0 Suture on the collateral ligament (Figures 13a and 13b).

**Note:** If additional sutures are needed, ULTRABRAID 2-0 sutures with needles and without needles are available. Refer to the “Ordering Information” section of this document.



**Figure 13a**



**Figure 13b**

13. Remove the distractor and the K-wires.

## Drill the bone tunnel using the Phalangeal Drill Guide

1. Place the distal tip of the Phalangeal Drill Guide, Short Offset (REF 72204321) at the ligament attachment site on the bony rise of the phalanx. Place the curve of the drill guide on the concavity of the phalanx. Place the proximal end of the drill guide  $30^{\circ} - 45^{\circ}$  to the sagittal plane (Figure 14).

**Note:** If a freehand tunnel is desired, use the Extra-Articular Drill Guide (REF 72204323).

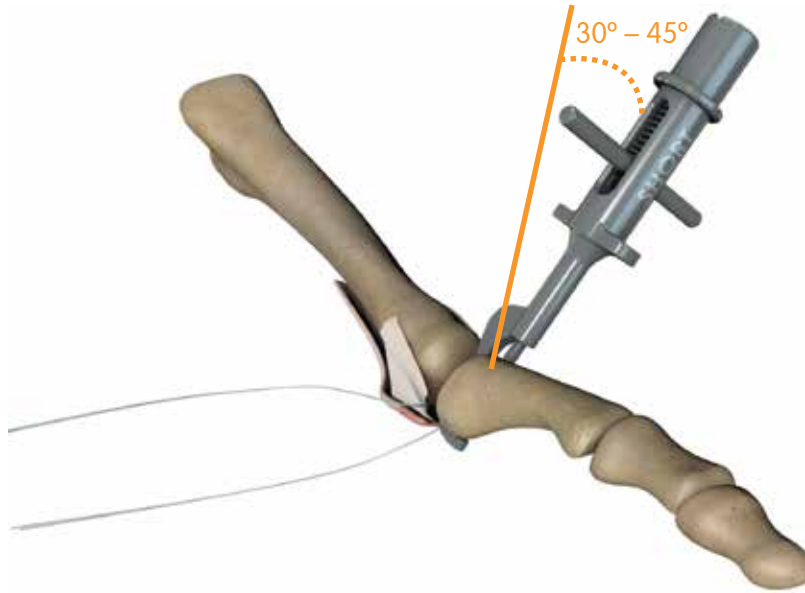


Figure 14: Concavity of the phalanx fully engaged

2. Drill the K-wire until the proximal end of the depth mark on the K-wire is flush with the proximal end of the drill guide (Figure 15).

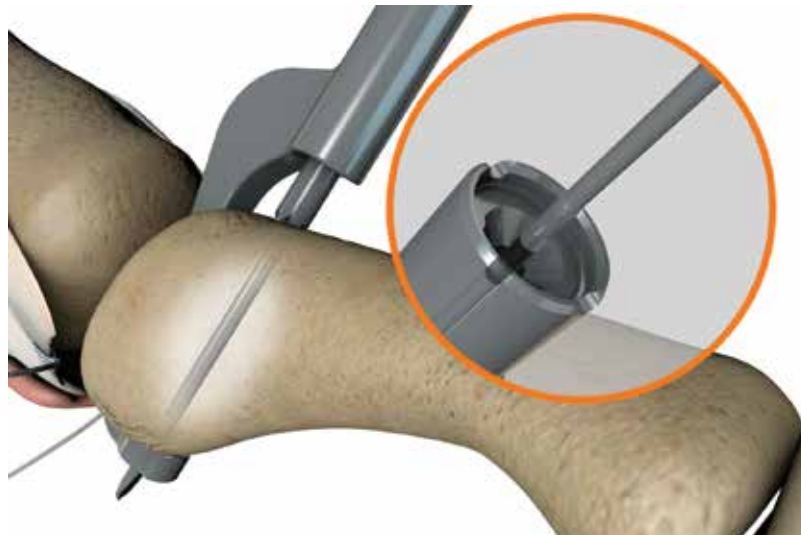


Figure 15

3. Insert the HAT-TRICK® Suture Shuttle assembly from the Unilateral Sterile Procedure Pack (REF 72204325) into the phalangeal drill guide (Figure 16a) until the suture shuttle bottoms out on proximal face of the drill guide (Figure 16b).

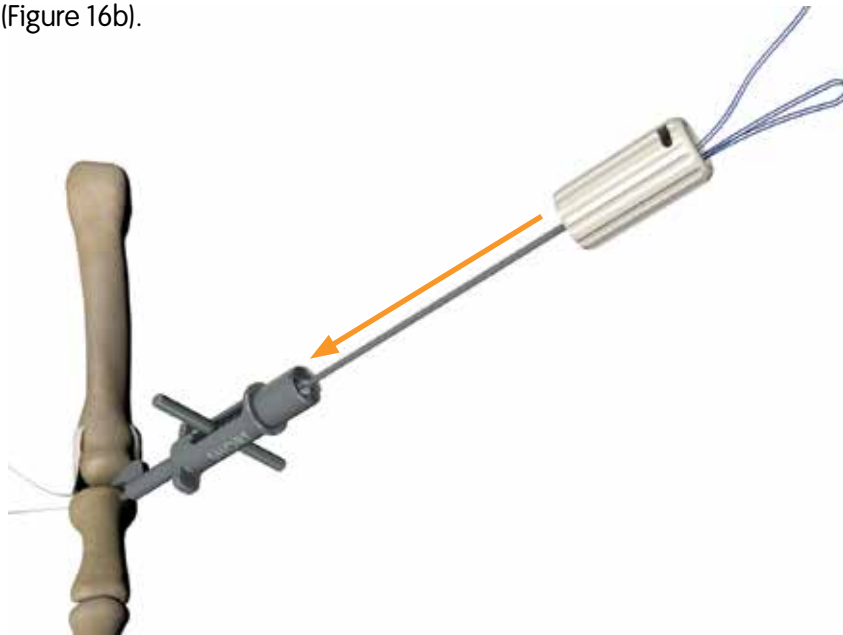


Figure 16a

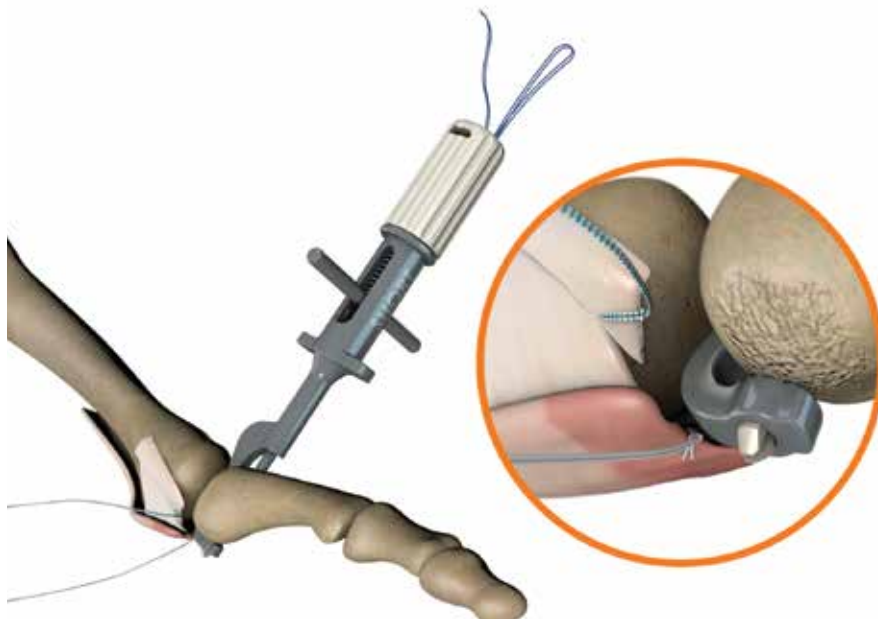


Figure 16b

4. Grasp the suture shuttle handle and remove the suture shuttle assembly, leaving the suture loop in place. Ensure that the suture's free ends are not through the loop.

5. Place the sutures in the groove on the proximal face of the drill guide (Figure 17).
6. Retract the T-Handle and gently rock the guide out of the joint space. Do not pull the suture when removing the drill guide (Figure 17).

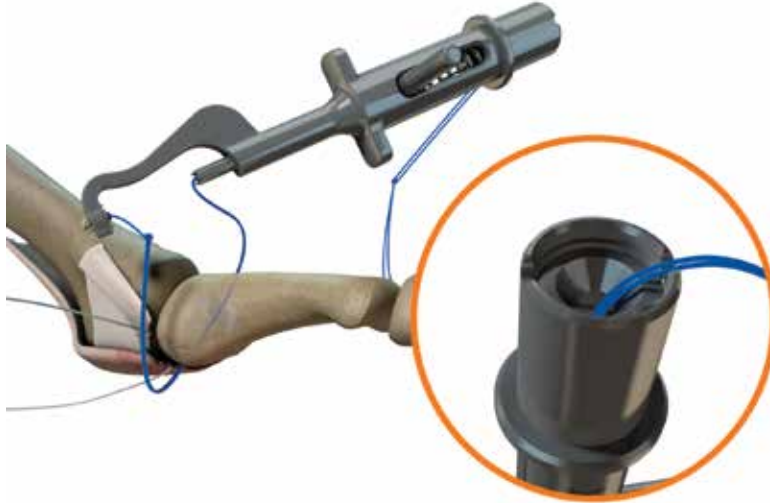

Figure 17: Remove the phalangeal drill guide from the joint space

7. Cut the suture between the distal suture knot and the pledget to free the drill guide (Figure 18).

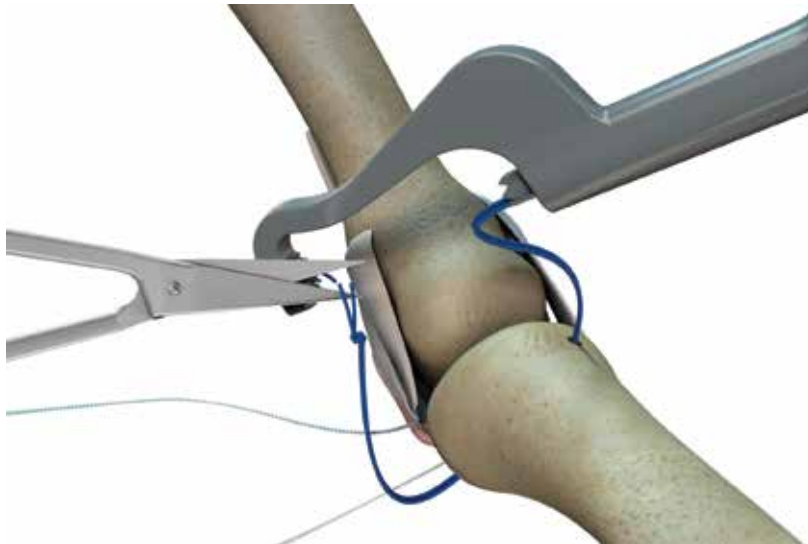



Figure 18

8. Leave the suture loop in the tunnel. Grasp the distal suture loop knot with a hemostat and remove the drill guide. Cut the monofilament suture at the proximal knot to create two monofilament suture strands.

9. Assemble the Modular Handle (REF 72204337) and HAT-TRICK® Cannulated Screw Tap (REF 72204339).



10. Insert the Nitinol Suture Passer from the Unilateral Procedure Pack through the handle and tap assembly. Pass the two strands of the monofilament sutures through the loop of the Nitinol Suture Passer and pull the suture through the handle and tap assembly. Tap the hole until the top of the laser mark is flush with the bone (Figure 19). Remove the handle and tap assembly from the two strands of the monofilament sutures. Remove the hemostat from the distal knot of the monofilament suture.

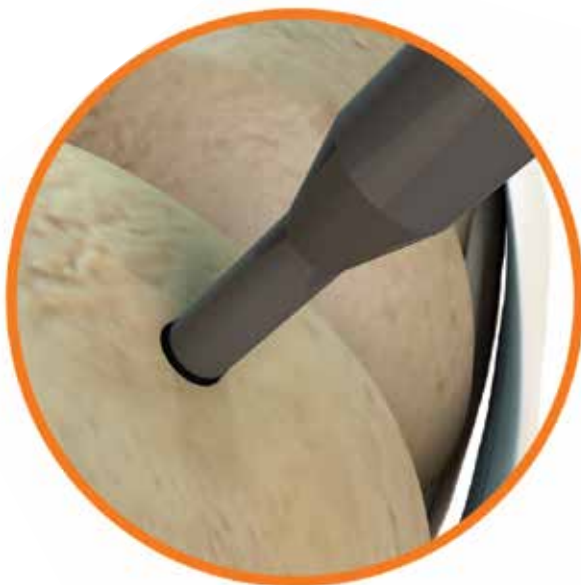


Figure 19

11. Pass all the sutures on the plantar side of the tunnel through the suture loop and pull them through the bone tunnel to the dorsal side (Figures 20a and 20b). Retrieve the sutures on the dorsal side of the tunnel (Figure 20c).

**Note:** The Nitinol Suture Passer, 8.8 inches (223.52mm) can be used to pass the sutures through the bone tunnels.

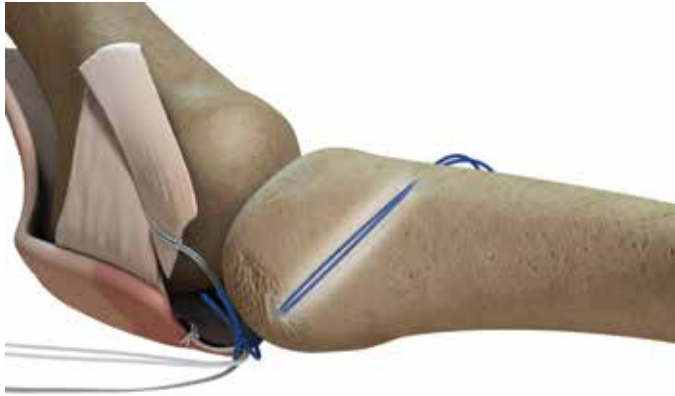


Figure 20a: Pass the sutures through bone tunnel

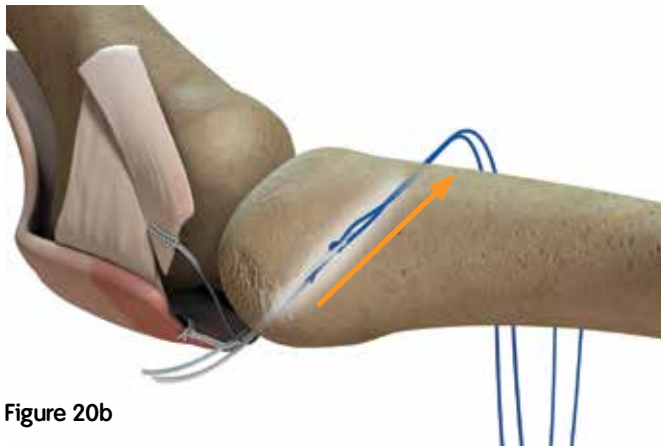


Figure 20b

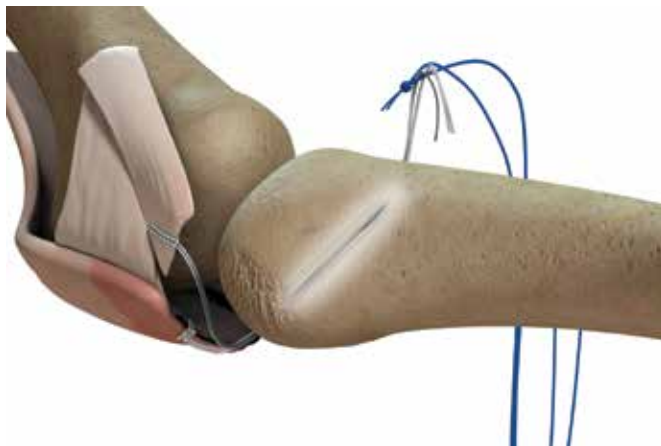


Figure 20c: Retrieve the sutures on the dorsal side



## Complete the repair

1. Assemble the cannulated screw, HAT-TRICK® Driver (REF 72204338) and the modular handle (not shown).
2. Insert the Nitinol Suture Passer, 8.8 inches (223.52mm) through the handle, driver and screw assembly (Figure 21a).
3. If fixing both the collateral ligament and the plantar plate, pass one limb from each of the plantar plate and collateral ligament sutures through the handle, driver and screw assembly (Figure 21b).



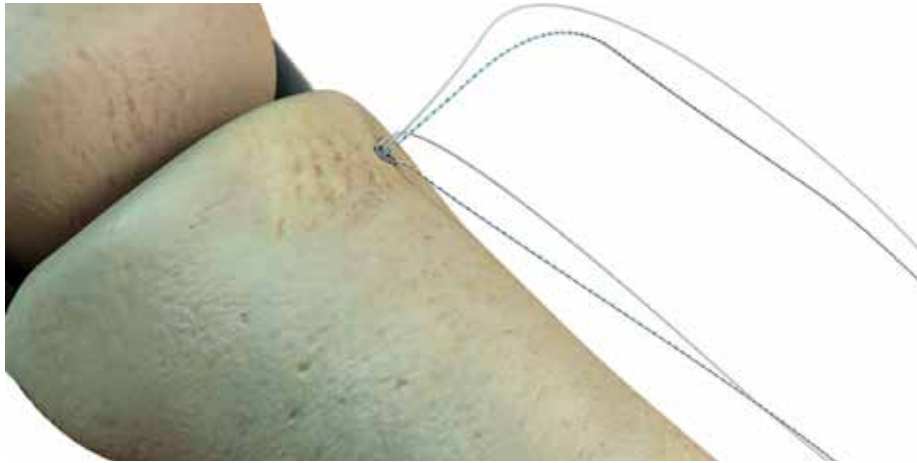
Figure 21a

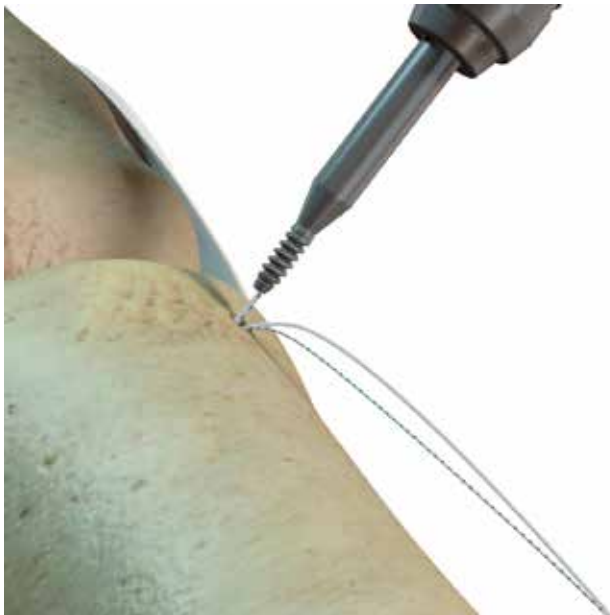

Figure 21b

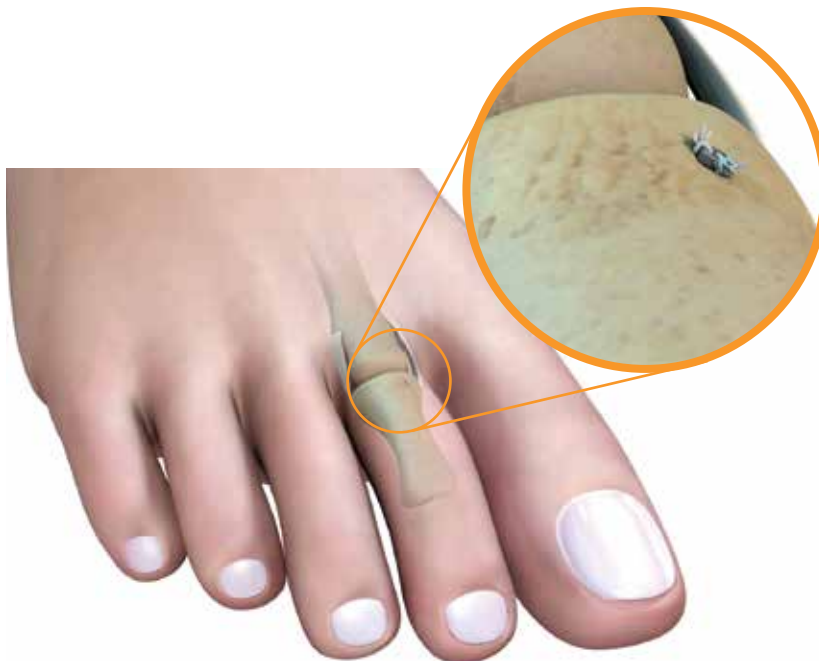

4. Hold the MTP joint in the reduced position with plantar flexion and a slight deviation to the repair side. Maintaining the suture tension, insert the cannulated screw into the tunnel until it is flush with the surface of the bone, being careful not to exert excessive force (Figure 22).



**Figure 22**

5. Tie the desired fixation knot over the shoulder of the screw to complete the repair (Figure 23).



**Figure 23: Final construct**

## Postoperative care\*

### **Weeks 1–6**

Apply a light bulky dressing, keeping the MTP joint in slight plantar flexion. The patient can do heel weight bearing as tolerated in a postoperative shoe with or without a walking aid. Gentle active ankle and MTP motion is encouraged.

### **Weeks 6–12**

Allow weight bearing as tolerated in a hard-sole shoe. Limit activity to walking only.

### **Weeks 12–16**

Return to low impact sports e.g. bike, pool, hiking, gym. No jumping, turning, twisting or high impact sports.

### **Week 16**

Resume full activities as tolerated.

\*The views and opinions expressed for postoperative care are solely those of the surgeon(s) and do not reflect the views of Smith & Nephew, Inc. In no event shall Smith & Nephew, Inc. be liable for any damages whatsoever (including, without limitation, damages for loss of business profits, business interruption, loss of business information, or other pecuniary loss) arising out of the use of or inability to use the expressed views.

# Ordering Information

To order the items used in these techniques, call +1 800 238 7538 in the US or contact an authorized Smith & Nephew representative. Prior to performing these techniques, consult the Instructions for Use documentation provided with individual components – including indications, contraindications, warnings, cautions and instructions.

## HAT-TRICK<sup>®</sup> MTP Repair Instrument Set

REF 72204305

Cat. No	Description
72204320	HAT-TRICK DART Suture Passer
72204321	HAT-TRICK Phalangeal Drill Guide, Short Offset
72204322	HAT-TRICK Phalangeal Drill Guide, Long Offset
72204323	HAT-TRICK Extra Articular Drill Guide
72204324	HAT-TRICK Suture Tensioner
72204337	HAT-TRICK Modular Handle
72204338	HAT-TRICK Driver Shaft, Cannulated Screw
72204339	HAT-TRICK TAP, Cannulated Screw
72204346	Cottle Elevator
72204349	Rasp, Double Ended
72204347	Small Joint Pin Distractor
72204348	Trigger Retractor
72204336	Snap Clamp
72204351	HAT-TRICK MTP Repair and Osteotomy Sterilization Tray

## HAT-TRICK Unilateral Sterile Procedure Pack

REF 72204325

Qty	Description
1 ea	HAT-TRICK Cannulated Screw, 2.5mm x 7.7mm
1 ea	HAT-TRICK DART Suture Passer Needle
1 ea	HAT-TRICK Suture Shuttle
1 ea	HAT-TRICK Nitinol Suture Passer, 8.8 inches
3 ea	1.6mm Drill Tip Wire, 150mm
1 ea	ULTRABRAID <sup>®</sup> 2-0 Co-braid White/Blue Suture, 24 inches
1 ea	ULTRABRAID 2-0 White Suture, 24 inches

## ULTRABRAID 2-0 Sutures (10 Pack)

Cat. No	Description
72204329	(10) ULTRABRAID 2-0 White suture, 24 inches
72204330	(10) ULTRABRAID 2-0 Co-braid White/Blue suture, 24 inches

## References

1. Hofstaetter SG, Hofstaetter, JG, Petroutsas, JA, Gruber F, Ritschl P, Trinka HJ. The Weil Osteotomy: A Seven-Year Follow-up. J Bone Joint Surg (Br) 2005;87-B:1507-11.
2. Beech I, Rees S, Tagoe M. A Retrospective Review of the Weil Metatarsal Osteotomy for Lesser Metatarsal Deformities: An Intermediate Follow-up Analysis. J Foot Ankle Surg 2005; 44(5):358-364.
3. Highlander P, VonHerbulis E, Gonzalez A, Britt J, Buchman J. Complications of the Weil Osteotomy. Foot Ankle Spec 2011; 4: 165-170.
4. Myerson M, Jung HG. The Role of Toe Flexor-to-Extensor Transfer in Correcting Metatarsophalangeal Joint Instability of the Second Toe. Foot Ankle Int 2005; 26: 675-679.
5. Internal Testing.

**Smith & Nephew, Inc.**  
150 Minuteman Road  
Andover, MA 01810  
USA

[www.smith-nephew.com](http://www.smith-nephew.com)

Telephone: 1-901-396-2121  
Information: 1-800-821-5700  
Orders and Inquiries: 1-800-238-7538

©2014 Smith & Nephew, Inc.  
All rights reserved.  
02488 V3 10/14