

REGENETEN[®] Bioinductive Implant is rapidly absorbed and replaced by tendon-like tissue within 6 months

Cell ingrowth by 5 weeks, with progressive maturation to tendon-like tissue



Study overview

- A retrospective study of biopsies taken between 5 weeks and 6 months following arthroscopic rotator cuff repair augmented with the REGENETEN Bioinductive Implant
- Biopsies were collected from 7 patients (6 full-thickness tears and 1 partial-thickness) requiring a second procedure
- Specimens were examined for host-tissue ingrowth, host-tissue maturation and host-implant biocompatibility



Key results

- At the earliest time period (5 weeks), the biopsy showed rapid host cell ingrowth and early collagen formation
- At 3 months, there was increased collagen formation, maturation and organization on the surface of the implant (Figure 1)
- By 6 months, the implant was no longer visible, with new tendon-like tissue and oriented collagen indicative of functional loading (Figure 2)
- No evidence of foreign body or inflammatory reactions at any time point

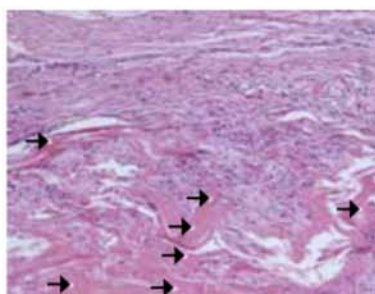


Figure 1. Photomicrograph of surface of implant at 3 months. Remnants of implant still present (→)

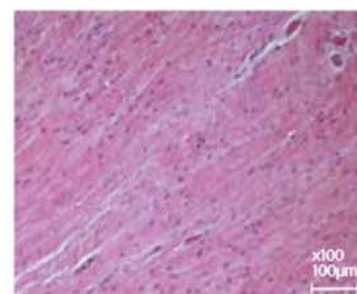


Figure 2. Photomicrograph of surface of implant at 6 months. No evidence of implant remaining

Images included with permission from Dr Craig L. Van Kampen.



Conclusion

The REGENETEN Bioinductive implant is the first to clinically demonstrate regeneration of tendon tissue. Biopsies demonstrated rapid host cell ingrowth and collagen formation, leading to progressive maturation and functional loading of new tissue.



Considerations

- Due to the relatively small sample size and the associated inter-patient variability to healing and graft uptake, the progress of tendon-like tissue has not been directly measured



Study citation

*Arnoczky SP, Bishai SK, Schofield B, et al. Histologic evaluation of biopsy specimens obtained after rotator cuff repair augmented with a highly porous collagen implant. *Arthroscopy* 2017;33(2):278-283.
Available at: [Arthroscopy: The Journal of Arthroscopy & Related Surgery](#)