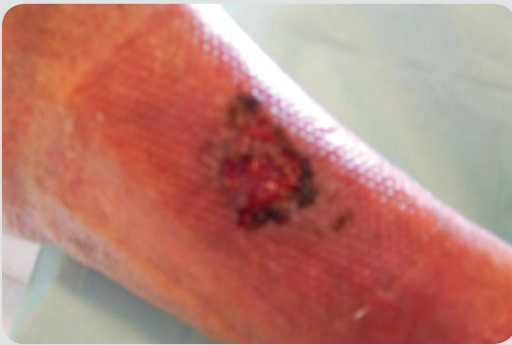


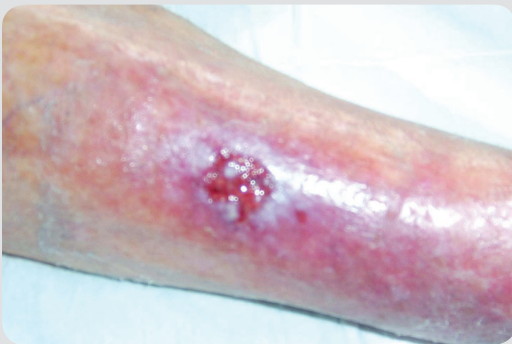ALLEVYN[®] Ag Gentle Border for an infected skin tear

Mary Ivey (CNC RCL),
Australia

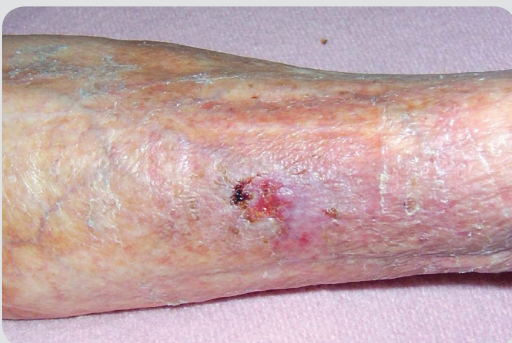 **smith&nephew**
ALLEVYN[®] Ag
GENTLE BORDER
Silicone Gel Adhesive
Antimicrobial Hydrocellular
Foam Dressing



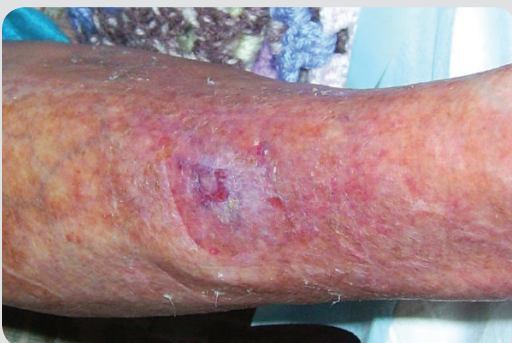13th April 2010 – At presentation



27th April 2010



3rd May 2010



Wound healed – 17th May 2010

Background

- 93-year-old woman with a history of falls
- Presented with a skin tear on her shin that had been present for 2 weeks, despite treatment with other advanced wound dressings

Aims and case challenges

- Promote healing
- Manage clinical signs of infection
- Reduce purulent exudate and odour
- Reduce pain and inflammation

Management

- ALLEVYN Ag Gentle Border dressing applied and changed every 1–2 days
- Dressing changes reduced as exudate decreased

Outcome

- Complete healing was achieved in approximately **4 weeks**

HIGHLIGHTS

- Reduces the clinical signs of infection
- Promotes wound healing
- Reduces pain and odour
- Manages exudate