

+ Evidence in focus

Evidence compendium:

ACTICOAT[◇]
Antimicrobial Barrier Dressings

May 2020

Smith+Nephew

Abbreviations

DFU – diabetic foot ulcer

IRR – incidence rate ratio

LOS – length of stay

MRSA – methicillin-resistant *Staphylococcus aureus*

MRSE – methicillin-resistant *Staphylococcus epidermis*

NNT – number needed to treat

NPWT – negative pressure wound therapy

NS – not significant

P. aeruginosa – *Pseudomonas aeruginosa*

PHMB – polyhexamethylene biguanide

PU – pressure ulcer

RCT – randomised controlled trial

S. aureus – *Staphylococcus aureus*

S. epidermis – *Staphylococcus epidermis*

SSD – silver sulphadiazine

SSI – surgical site infection

TBSA – total body surface area

VAS – visual analogue scale

VLU – venous leg ulcer

WUWHS – World Union of Wound Healing Societies

Navigation icons



Burns



Acute wounds



Use with NPWT



Safety and tolerability



Chronic wounds



Antibiotic-resistant organisms



Health economics / costs



Home

ACTICOAT[◇] Antimicrobial Barrier Dressings

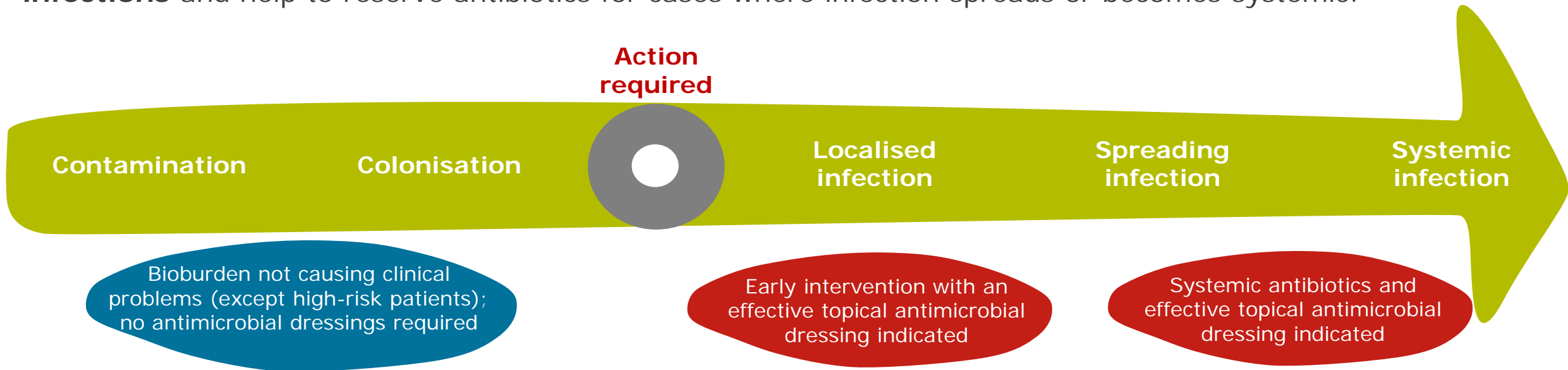
Role in infection control protocols and antimicrobial stewardship



Effective antiseptics, such as ACTICOAT Dressings, can be used to **minimise transmission of antibiotic-resistant organisms** as part of institutional infection control procedures.¹

Appropriate early use and stewardship on local wound infections, as part of local infection management procedures, can help to **reduce the need for systemic antibiotic therapy**.¹

Consensus recommendations advocate **appropriate use of silver dressings to manage local infections** and help to reserve antibiotics for cases where infection spreads or becomes systemic.¹



Woodmansey EJ and Roberts CD. *Int Wound J.* 2018;15:1025-1032.

ACTICOAT[◇] Antimicrobial Barrier Dressings

Substantial evidence base



Intended use and indications

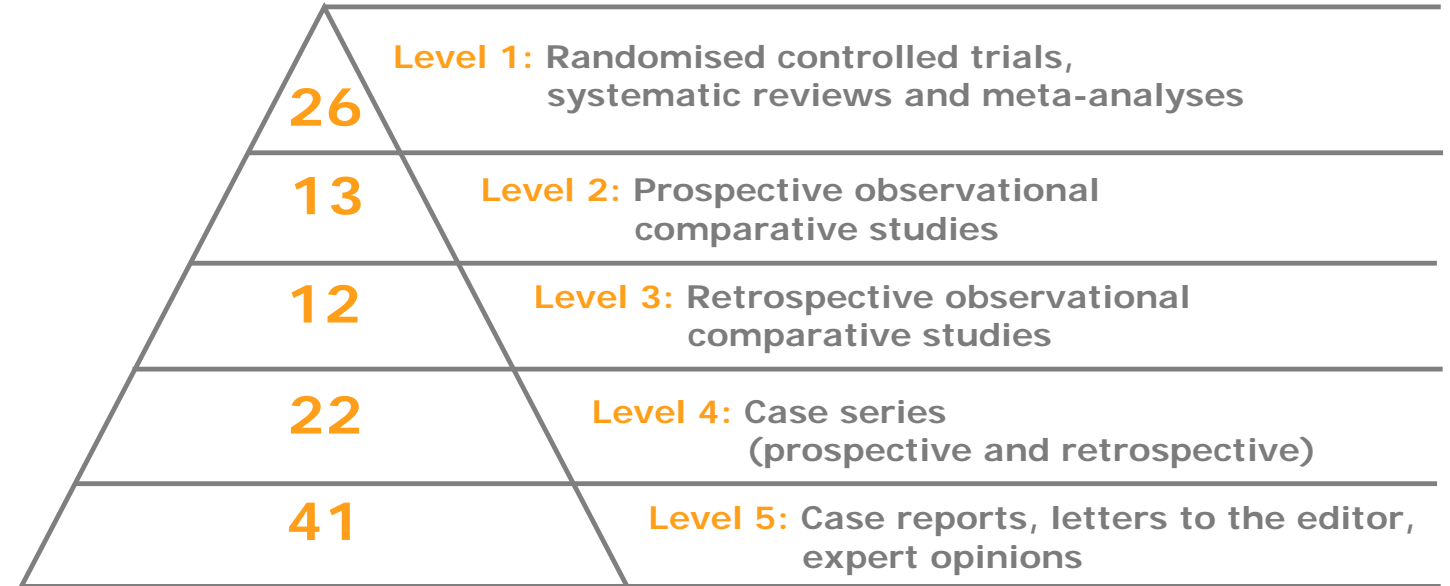
ACTICOAT[◇] 3 Antimicrobial Barrier Dressing and ACTICOAT[◇] 7 Antimicrobial Barrier Dressing can be used over partial and full thickness wounds such as pressure ulcers, venous ulcers, diabetic ulcers, burns, and recipient graft sites.

ACTICOAT[◇] FLEX 3 Antimicrobial Barrier Dressing and ACTICOAT[◇] FLEX 7 Antimicrobial Barrier Dressing are indicated for use over partial and full thickness wounds such as burns, recipient graft sites, surgical sites, pressure ulcers, venous ulcers and diabetic ulcers.

ACTICOAT 3 Antimicrobial Barrier Dressing, ACTICOAT 7 Antimicrobial Barrier Dressing, ACTICOAT[◇] FLEX 3 Antimicrobial Barrier Dressing and ACTICOAT[◇] FLEX 7 Antimicrobial Barrier Dressing may all be used on infected wounds where the infection should be inspected and treated as per local clinical protocol. They may all be slit and used as a wound contact layer in combination with NPWT for a period of up to 3 days.

ACTICOAT 3 Antimicrobial Barrier Dressing 5cm x 5cm (2in x 2in) is indicated for use over catheter insertion sites and on infected catheter insertion sites, where the infection should be inspected and treated as per local clinical protocol.

Evidence pyramid



Information correct up to: 30 March 2020

The evidence compendium also includes **eight more published studies** (eg, cost analyses and preclinical studies) that are classified as 'other'.

This evidence compendium contains a summary of the most relevant publications about ACTICOAT Dressings, and may not include all publications due to the volume of studies.

Evidence by topic

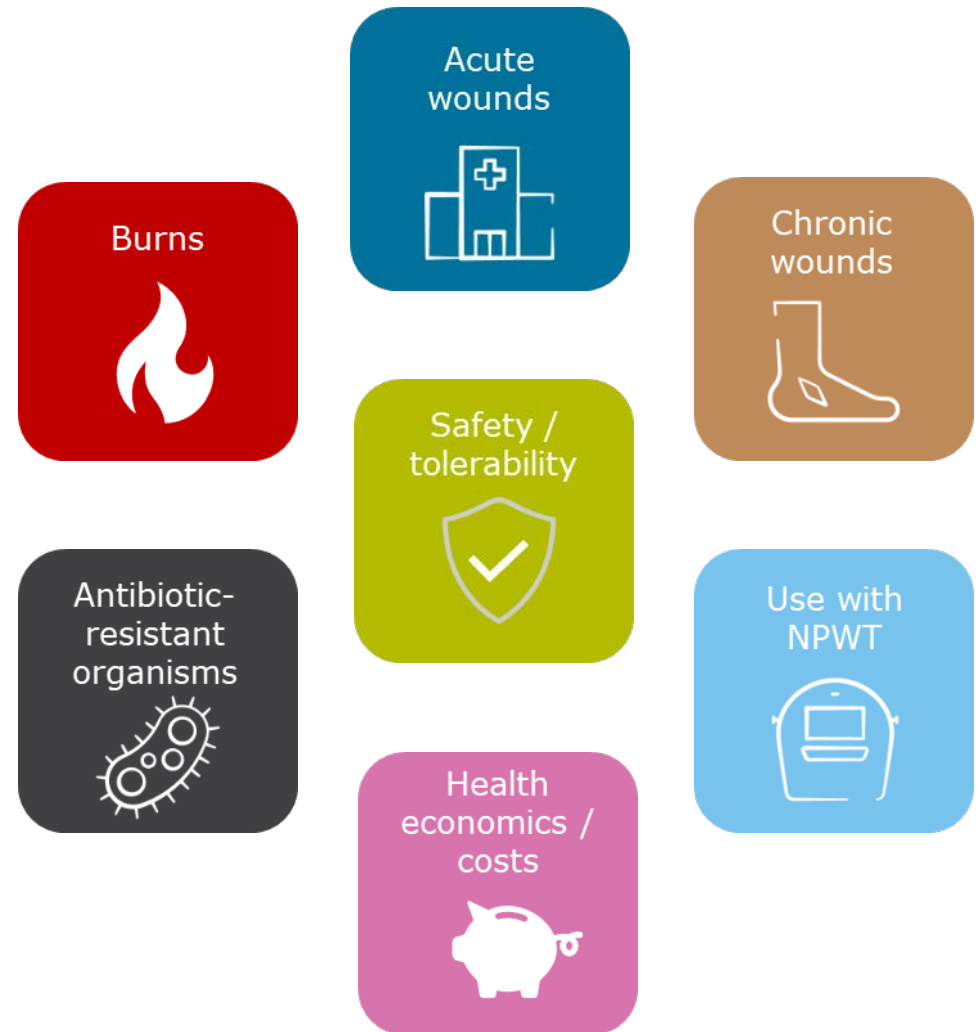Contents

Please select the relevant section to view the key studies and their outcomes that support ACTICOAT[◇] Antimicrobial Dressings.

Navigation icons will be displayed where outcomes from the same study are included in multiple sections.

The following studies are available in **Evidence in focus** format and can be downloaded from the Smith+Nephew Education and Evidence website:

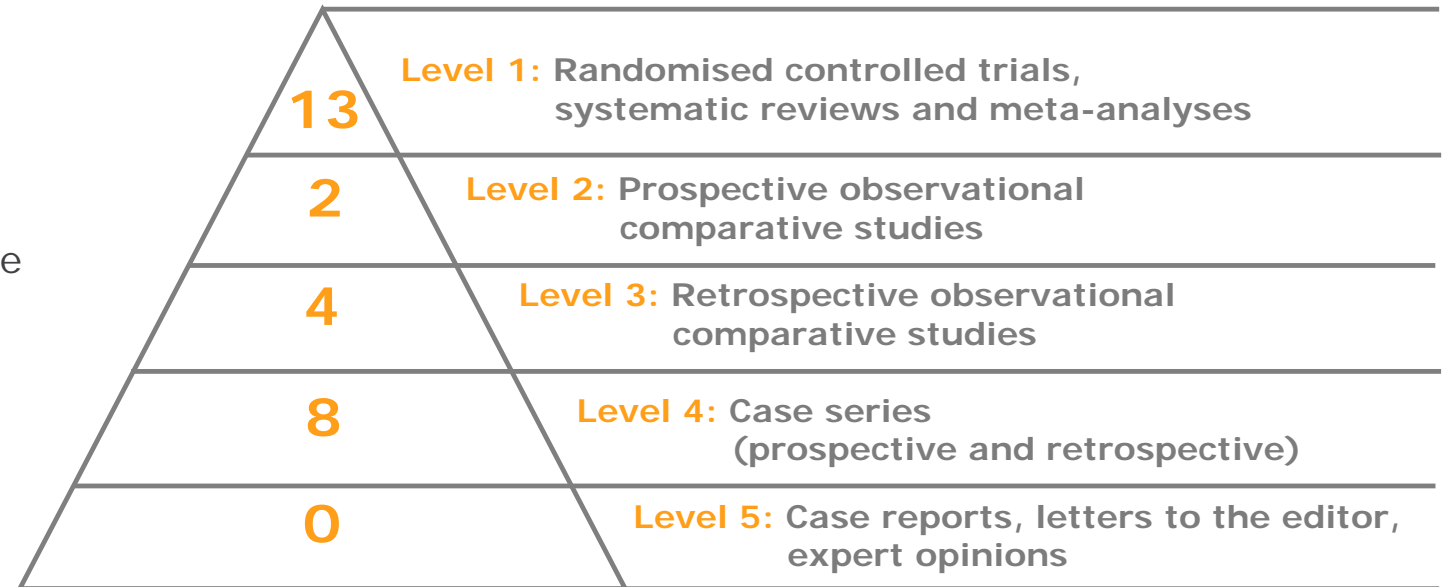
- [Gago M, et al. \(2008\) Evidence in focus²](#)
- [Glik J, et al. \(2018\) Evidence in focus³](#)
- [Nherera L, et al. \(2018\) Evidence in focus⁴](#)
- [Nherera L, et al. \(2017\) Evidence in focus⁵](#)
- [Woodmansey EJ, et al. \(2018\) Evidence in focus¹](#)



This section summarises key studies supporting the use of ACTICOAT[◇] Antimicrobial Dressings in **burns**.

Studies that are included elsewhere in the evidence compendium can be identified by navigation icons, which link to the relevant sections.




Evidence pyramid







Information correct up to: 30 March 2020


Three more published studies that are classified as 'other' evidence.







Author (icons link to other sections)	Evidence level	Study overview	Key outcomes / conclusions
Gravante G, et al. <i>Ann Plastic Surgery.</i> 2009; 63(2): 201–204. ⁶	Level 1 (meta-analysis)	<ul style="list-style-type: none"> • Meta-analysis of five RCTs • 285 patients (105 ACTICOAT[◊] Dressing and 180 silver nitrate and SSD) 	ACTICOAT Dressing patients experienced less pain during dressing change than with the other silver formulations ($p < 0.0001$). Patients treated with ACTICOAT Dressing had a significantly lower incidence of infection than those treated with older silver formulations (9.5 vs 27.8% patients; $p < 0.001$).
Nherera L, et al. <i>Burns.</i> 2017; 43(5): 939–948. ⁵	Level 1 (meta-analysis)	<ul style="list-style-type: none"> • Systematic literature review and meta-analysis • Superficial and deep partial thickness burns • ACTICOAT[◊] Dressing, SSD and silver nitrate • 8 studies versus SSD (n=1,391) • 1 study versus silver nitrate (n=30) 	60% reduction in need for surgical procedures with ACTICOAT Dressing versus SSD ($p = 0.00001$) potentially due to reduced infection incidence and shorter time for epithelialisation. LOS was 4.74 days shorter with a 79% reduction in infection rate using ACTICOAT Dressing versus SSD (both $p \leq 0.005$).
Gee Kee EL, et al. <i>Burns.</i> 2015; 41(5): 946–955. ⁷	Level 1	<ul style="list-style-type: none"> • RCT • Paediatric medium size acute partial thickness burns • ACTICOAT Dressing versus ACTICOAT Dressing with Mepitel™ versus Mepilex™ Ag <ul style="list-style-type: none"> • 31 patients with ACTICOAT Dressing • 32 patients with ACTICOAT Dressing with Mepitel™ • 33 patients with Mepilex™ Ag 	No infections were detected during the study. Adjusting for depth, ACTICOAT Dressing significantly increased the expected days to full re-epithelialisation by 40% (IRR=1.40; 95% CI: 1.14–1.73, $p < 0.01$) and ACTICOAT Dressing with Mepitel™ significantly increased the expected days to full re-epithelialisation by 33% (IRR=1.33; 95% CI: 1.08–1.63, $p = 0.01$) compared with Mepilex™ Ag. Nursing staff rated ACTICOAT Dressing with Mepitel™ and Mepilex™ Ag the easiest to remove from both hands or feet and flat surfaces. ACTICOAT Dressing with Mepitel™ was rated as the easiest to apply to hands or feet and flat surfaces.


Author (icons link to other sections)	Evidence level	Study overview	Key outcomes / conclusions
Huang Y, et al. <i>Burns</i> . 2007; 33(2): 161–166. ⁸  	Level 1	<ul style="list-style-type: none"> • RCT • 166 wounds (98 patients) • Mean burn size 54.2% TBSA • ACTICOAT Dressing and SSD 	<p>Bacterial clearance rates on days 6 and 12 after application of treatment for ACTICOAT Dressing patients were significantly higher than SSD patients ($p < 0.05$).</p> <p>Clearance rates were 16.7% (day 6) and 26.7% (day 12) for the ACTICOAT Dressing group in contrast with 11.5% and 19.2%, respectively, for SSD. Healing time was 3.35 days shorter with ACTICOAT Dressing versus SSD (12.42 vs 15.79 days).</p>
Hyland EJ, et al. <i>Int J Burns Trauma</i> . 2018; 8(3): 63–67. ⁹	Level 1	<ul style="list-style-type: none"> • RCT • Paediatric mid-dermal burns ($\geq 1\%$ TBSA) • ACTICOAT Dressing versus BIOBRANE[◊] Dressing • 10 patients per group 	<p>More infections were reported with BIOBRANE Dressing than ACTICOAT Dressing (6 vs 1 child; $p = 0.057$).</p> <p>Healing time was shorter with BIOBRANE Dressing than ACTICOAT Dressing, but this was not significant (19 vs 26.5 days; $p = \text{NS}$).</p> <p>Median number of dressing changes was similar with ACTICOAT Dressing and BIOBRANE Dressing (5.0 vs 5.5; $p = \text{NS}$).</p> <p>Fewer children in the ACTICOAT Dressing group had a positive swab result than in the BIOBRANE Dressing group (4 vs 7; $p = \text{NS}$).</p>
Muangman P, et al. <i>J Med Assoc Thai</i> . 2006; 89(7): 953–958. ¹⁰	Level 1	<ul style="list-style-type: none"> • RCT • Partial thickness burns ($< 25\%$ TBSA) • 50 patients (25 ACTICOAT Dressing; 25 SSD 1%) 	<p>Fewer ACTICOAT Dressing patients developed wound colonisation (64 vs 88%) or a wound infection (12 vs 16%) compared with SSD.</p> <p>Mean pain score with ACTICOAT Dressing was lower than SSD (4 vs 5).</p>
Muganza A, et al. <i>Global Journal of Human-Social Science</i> . 2014; 14(6): 1–12. ¹¹ 	Level 1	<ul style="list-style-type: none"> • RCT • Partial thickness burns ($> 10\%$ to $\leq 40\%$) • ACTICOAT Dressing with BIOBRANE Dressing and MELOLIN[◊] Dressing vs SSD • ACTICOAT Dressing with BIOBRANE Dressing, $n = 49$ (paediatrics $n = 26$) • Standard dressing, $n = 47$ (paediatrics $n = 19$) 	<p>ACTICOAT Dressing had higher healing rates than SSD (81.6 vs 78.7%; $p = \text{NS}$), particularly in paediatrics (86.6 vs 68.4%; NNT of 6).</p> <p>Overall, median LOS was longer with BIOBRANE Dressing than with ACTICOAT Dressing (18 vs 17 days; $p = \text{NS}$), but was shorter in both the adult and paediatric subgroups (16 vs 17 days; 19 vs 20 days, respectively; $p = \text{NS}$).</p> <p>Median dressing changes were lower for ACTICOAT Dressing with BIOBRANE Dressing in adults ($p = 0.0003$) and paediatrics ($p = 0.039$).</p> <p>The authors recommended use of ACTICOAT Dressing with BIOBRANE Dressing in a paediatric setting and adapted their standard of care.</p>


Author (icons link to other sections)	Evidence level	Study overview	Key outcomes / conclusions
Palombo M, et al. <i>Burns</i> . 2011; 37: S8–S9. ¹²	Level 1	<ul style="list-style-type: none"> • RCT • 17 patients with deep second degree or full thickness burns • ACTICOAT[◊] FLEX 3 Dressing versus paraffin gauze used either after: <ul style="list-style-type: none"> – Escharectomy (n=8) – Escharectomy and split-thickness skin graft and Matriderm[®] (n=6) – Full thickness burns (n=3) 	<p>Bacterial cultures were negative in the ACTICOAT Dressing group and were positive in 5 patients in the control group. Optimal wound-bed preparation in 8 patients with only escharectomy; good graft-take (from 75 to 100%) in the remaining 9 patients, including those treated with Matriderm[®]. The authors stated that ACTICOAT FLEX 3 Dressing had an excellent bactericidal effect and extended the advantages to partial thickness burns and grafts.</p>
Silver GM, et al. <i>J Burn Care Res</i> . 2007; 28(5): 715–719. ¹³ 	Level 1	<ul style="list-style-type: none"> • RCT • 20 burns requiring meshed autografts • Mean TBSA 17.9% • ACTICOAT[◊] Dressing versus Sulfamylon[®]-soaked EXU-DRY Dressing 	<p>No differences in wound healing endpoints. Reduction in the frequency of dressing change with ACTICOAT Dressing versus Sulfamylon[®]-soaked EXU-DRY Dressing (3 vs 4; p=0.01). Ease of application and nurse satisfaction were greater with ACTICOAT Dressing than with Sulfamylon[®]-soaked EXU-DRY Dressing.</p>
Tredget EE, et al. <i>J Burn Care Rehabil</i> . 1998; 19(6): 531–537. ¹⁴	Level 1	<ul style="list-style-type: none"> • RCT • 30 patients (2 burns each) • Mean TBSA 27.7% with total full thickness injury of 19.5% • ACTICOAT Dressing versus gauze dressings with 0.5% silver nitrate 	<p>Burn wound sepsis in 5 of 25 biopsies for ACTICOAT Dressing compared with 16 of 25 biopsies for silver nitrate. Secondary bacteraemia arising from infected wounds was less frequent with ACTICOAT Dressing than silver nitrate (1 vs 5; 17 wounds per group). ACTICOAT Dressing was less painful on removal; mean VAS pain score was 2.6 for ACTICOAT Dressing and 3.9 for silver nitrate (p<0.05).</p>
Varas RP, et al. <i>J Burn Care Rehabil</i> . 2005; 26(4): 344–347. ¹⁵	Level 1	<ul style="list-style-type: none"> • RCT • Partial thickness burns • Mean TBSA 14.6% • ACTICOAT Dressing versus SSD • 14 patients (two burns each) 	<p>Less pain associated with dressing changes for ACTICOAT Dressing compared with SSD (mean pain score: 3.2 for ACTICOAT Dressing vs 7.9 for SSD; p<0.0001).</p>





Author (icons link to other sections)	Evidence level	Study overview	Key outcomes / conclusions
Verbelen J, et al. <i>Burns</i> . 2014; 40(3):416–427. ¹⁶	Level 1	<ul style="list-style-type: none"> • RCT • Partial thickness burns ($\leq 40\%$ TBSA) • ACTICOAT[◊] Dressing versus Aquacel[™] Ag • 50 patients in each group 	<p>Mean healing time was similar with ACTICOAT Dressing and Aquacel[™] Ag (16.1 vs 15.1 days; $p=NS$).</p> <p><i>S. aureus</i> contamination worsened in the ACTICOAT Dressing group ($p=0.002$) and Aquacel[™] Ag group ($p=0.038$).</p> <p>No statistically significant differences in the number of signs of infection observed or worst signs of infection observed.</p>
Wood F, et al. <i>Burns</i> . 2012; 38(6):830–839. ¹⁷ 	Level 1	<ul style="list-style-type: none"> • RCT • Paediatric scalds • ACTICOAT Dressing with INTRASITE[◊] Dressing and DuoDERM[™] (standard treatment; $n=4$) versus BIOBRANE[◊] Dressing ($n=4$) and BIOBRANE Dressing with autologous cell suspension ($n=5$) • Median total TBSA of 4% 	<p>Median complete wound healing time was 16 days with BIOBRANE Dressing and BIOBRANE Dressing + autologous cell suspension group versus 36.5 days for ACTICOAT Dressing + INTRASITE Dressing + DuoDERM[™].</p> <p>Healing rates at days 10 and 21, respectively, were:</p> <ul style="list-style-type: none"> • 95% and 100% for BIOBRANE Dressing + autologous cell suspension. • 83.2% and 97.7% for BIOBRANE Dressing. • 71.2% and 90.1% for ACTICOAT Dressing + INTRASITE Dressing + DuoDERM[™]. <p>Median number of dressing changes was 12.5 for ACTICOAT Dressing + INTRASITE Dressing + DuoDERM[™], 7 for BIOBRANE Dressing and 5 for BIOBRANE Dressing + autologous cell suspension.</p>
Argirova M, et al. Book chapter: <i>Skin Grafts-Indications, Applications and Current Research</i> . 2011: 237–264. ¹⁸  	Level 2	<ul style="list-style-type: none"> • Prospective cohort • Paediatric burns (78 superficial burns, 19 deep burns, 5 excised burns, 5 autografts, 5 donor sites) • Mean TBSA of 7.89% • ACTICOAT Dressing/ACTICOAT[◊] FLEX 3 Dressing/ACTICOAT[◊] FLEX 7 Dressing ($n=68$) versus SSD ($n=43$) 	<p>97% of children had no bacterial growth until end of treatment. ACTICOAT Dressing and ACTICOAT FLEX Dressing were effective for superficial, deep and excised burns, autografts and donor sites. In superficial burns, mean epithelialisation time was 12.98 days, second (IIA) degree burns epithelialized within 5-6 days.</p> <p>The authors considered ACTICOAT Dressing to be highly efficient for application in superficial burns or second (IIA and IIB) degree, pre-surgical treatment of patients, prophylaxis and treatment of infection in burns, treatment of donor sites, excised sites and autografts.</p>

Author (icons link to other sections)	Evidence level	Study overview	Key outcomes / conclusions
Demling RH, et al. <i>Burns.</i> 2002;28(3):264–266. ¹⁹	Level 2	<ul style="list-style-type: none"> • Cohort study • 20 patients with meshed skin grafts (2 wounds, each one received different treatment) • Deep burns (15–40% TBSA) • ACTICOAT[◊] Dressing versus gauze dressings moistened with an antimicrobial solution (neomycin and polymyxin) 	<p>Significant increase in the re-epithelialisation rate for the ACTICOAT Dressing group at day 4 and day 7. 40% increase in the rate of re-epithelialisation for the ACTICOAT Dressing group; at the end of 7 days. All wounds were closed in the ACTICOAT Dressing group in contrast with 55% (±10%) for the antibiotic solution.</p>
Peters DA, et al. <i>J Burn Care Res.</i> 2006;27:198–201. ²⁰	Level 2	<ul style="list-style-type: none"> • Cohort study • Medium-sized paediatric burns (>20% TBSA) • 30 prospective ACTICOAT Dressing patients with 73 matched historical controls (SSD) 	<p>Mean numbers of debridement/graft procedures were lower for ACTICOAT compared with SSD (0.3±0.466 vs 0.54±0.650; p=0.03). Mean LOS was 13 days less in the ACTICOAT Dressing group compared with SSD (0.83 vs 13.85 days; p<0.001). There were significantly fewer complications with ACTICOAT Dressing than with SSD (p=0.035).</p>
Cuttle L, et al. <i>Burns.</i> 2007;33:701–707. ²¹ 	Level 3	<ul style="list-style-type: none"> • Cohort study • Partial- or full-thickness burns (<20% TBSA) • ACTICOAT Dressing versus Silvazine™ • 328 paediatric patients treated with Silvazine™ between January 2000 and June 2001 compared with 241 patients treated with ACTICOAT Dressing between July 2002 and July 2003 	<p>Only one patient in each group had positive blood cultures. For patients not requiring grafting, the time to re-epithelialisation was significantly shorter for ACTICOAT Dressing than Silvazine™ (p=0.047). Mean re-epithelialisation time was 3.4 days shorter with ACTICOAT Dressing than Silvazine™ (14.9 vs 18.3 days). Percentage of children requiring grafting was significantly less in the ACTICOAT Dressing group versus Silvazine™ (15.4 vs 25.6%; p=0.001).</p>

Author (icons link to other sections)	Evidence level	Study overview	Key outcomes / conclusions
Fong J, et al. <i>Burns</i>. 2005; 31(5): 562–567. ²²  	Level 3	<ul style="list-style-type: none"> • Cohort study • Burns (superficial to deep partial thickness) • Mean TBSA 9.0–9.5% • Audit comparing ACTICOAT[◊] Dressing (19 patients) with Silvazine[™] (51 patients) 	A reduction in the incidence of burn wound cellulitis for ACTICOAT Dressing compared with Silvazine [™] (10.5 vs 55.0%). Antibiotic usage was reduced with ACTICOAT Dressing compared with Silvazine [™] (5.2 vs 57.0%). Mean LOS was 4.75 days shorter with ACTICOAT Dressings than with Silvazine [™] (12.50 vs 17.25 days).
Glik J, et al. <i>Int Wound J</i>. 2018; 15(3): 344–349. ³  	Level 3	<ul style="list-style-type: none"> • Retrospective case series • Burns (unspecified) • Mean TBSA was 18.4% • Silver dressings (ACTICOAT[◊] Dressing/ ACTICOAT[◊] FLEX 3 Dressing) and antiseptics versus antibiotics and antimycotics (n=2,000) • Implementation of a new management strategy 	The number of sepsis cases decreased from 60 in 2014 to 46 in 2016, with a decrease in cases caused by <i>P. aeruginosa</i> (12 cases in 2014 and 1 case in 2016). Mortality rate decreased: 5.7 cases in 2014 and 4.9 cases in 2016. Sensitivity to most antibiotics used to treat <i>P. aeruginosa</i> infections increased in 2016.
Strand O, et al. <i>Ann Burns Fire Disasters</i>. 2010; 23(4): 182–185. ²³  	Level 3	<ul style="list-style-type: none"> • Retrospective case review • Paediatric burns (mostly water and flames) • Mean TBSA % was 5.74 to 5.97% • Before (2001) and after (2004 and 2007) implementation of a new care protocol • ACTICOAT Dressing, INTRASITE[◊] GEL Dressing and ALLEVYN[◊] ADHESIVE Dressing • In 2001, 292 paediatric burn patients (48 in-patients); in 2004, 371 patients (69 in-patients); in 2007, 397 patients (57 in-patients) 	Significant reductions in LOS (from 12.5 in 2001 to 4.5 days in 2007; p<0.001). Reduction in antibiotic usage for hospitalised patients (from 70 to 25%; p<0.001).

Author (icons link to other sections)	Evidence level	Study overview	Key outcomes / conclusions
Tonkin C, et al. <i>Primary Intention.</i> 2005; 13(4): 163–168. ²⁴ 	Level 3	<ul style="list-style-type: none"> • Cohort study • Four periodic clinical audits • Burns (mostly flame; no full thickness burns) • Mean TBSA was 9.3% • ACTICOAT Dressing (n=36) versus SSD (n=36) 	<p>Fewer standard ACTICOAT Dressing patients had surgery than SSD patients (25 vs 67%).</p> <p>Only 6% of ACTICOAT Dressing patients experienced wound breakdown compared to 25% of SSD patients.</p> <p>Mean LOS for Standard ACTICOAT Dressing was 8.8 days compared with 15.1 days for SSD patients (p=0.045).</p>
Andreone A, et al. <i>Stem Cells International.</i> 2019: 1–9. Article ID 8636079 ²⁵	Level 4	<ul style="list-style-type: none"> • Retrospective case series • Massive and chronic full thickness burns • Mean TBSA was 22.5% • Integra™ covered with ACTICOAT[◇] Dressing (to prep the wound) prior to spray on skin • 5 patients 	<p>Observed fast and complete skin graft integration on average after 7-10 days using platelet rich fibrin/micrograft spray-on skin treatment with ACTICOAT Dressing.</p>
Jain A, et al. <i>JCDR.</i> 2019; 13(11): PC05–PC08. ²⁶	Level 4	<ul style="list-style-type: none"> • Prospective case series • Second degree superficial partial-thickness burns (various aetiologies, mostly scalds) • ACTICOAT Dressing • 30 patients 	<p>All patients showed healing during first week (partial epithelialisation, no surrounding inflammation).</p> <p>Wounds of 4 patients epithelialised completely within 1 week requiring no more dressings.</p> <p>18 patients took up to 2 weeks and 8 patients required >2 weeks for epithelialisation.</p> <p>Mean LOS was 12.2 days for 22 patients who were admitted and 8.9 days for all 30 patients.</p> <p>The authors stated that the advantages of ACTICOAT Dressings were ease of use, powerful antibacterial effect, lower frequency of dressing change, good moulding, short time of wound clearing and epithelialisation, and painless dressing change.</p>

Author (icons link to other sections)	Evidence level	Study overview	Key outcomes / conclusions
Moiemen NS, et al. <i>Burns</i> . 2011; 37(1): 27–35. ²⁷ 	Level 4	<ul style="list-style-type: none"> • Cohort study • 6 patients with burns >20% TBSA (grafted and non-grafted areas and donor sites) • Evaluated serum silver levels, biochemistry and haematology before, during and after application of ACTICOAT Dressing 	<p>Median maximum serum silver level was 200.3µg/L, reached at a median of 9.5 days following initial dressing application. This decreased to a median of 164.8µg/L at the end of the treatment period and to a median of 8.2 µg/L at the end of follow-up.</p> <p>Serum silver levels were elevated but remained similar to that reported following the use of SSD.</p> <p>There was one instance of dressing-related graft loss (non-serious).</p>
Lonie S, et al. <i>Burns</i> . 2017; 43(3): 509–513. ²⁸	Level 4	<ul style="list-style-type: none"> • Retrospective case series • Paediatric scalds • ACTICOAT[◊] Dressing used for partial-thickness burns • n=322 	<p>Mean time for scalds to heal was 15.4 days.</p> <p>The authors reported improved healing of scalds after widespread adoption of ACTICOAT Dressing and consequently a reduced need for surgical intervention.</p>
Rustogi R, et al. <i>Burns</i> . 2005; 31(7): 878–882. ²⁹	Level 4	<ul style="list-style-type: none"> • Retrospective case series • Neonatal burns • TBSA <30% • ACTICOAT Dressing or ACTICOAT[◊] 7 Dressing • n=8 	<p>Four burns fully re-epithelialised without evidence of local infection.</p> <p>Mean time to re-epithelialisation was 21 days.</p>
Selvarajah D, et al. <i>Int J Bruns Trauma</i> . 2019; 9(4): 82–87. ³⁰	Level 4	<ul style="list-style-type: none"> • Retrospective case series • Paediatric mid-dermal torso burns (mostly scalds) • ACTICOAT Dressing versus BIOBRANE[◊] Dressing • 64 patients in the ACTICOAT Dressing group, 14 in the BIOBRANE Dressing group 	<p>Median time to complete healing was quicker with ACTICOAT Dressing than BIOBRANE Dressing (13 vs 17 days; p=NS).</p> <p>Healing rate was 56% for ACTICOAT Dressing and 71% for BIOBRANE Dressing.</p> <p>LOS was shorter with ACTICOAT Dressing than BIOBRANE Dressing in ungrafted patients (0.88 vs 5.08 days, p=0.004).</p> <p>LOS was also shorter with ACTICOAT Dressing than BIOBRANE Dressing for all (grafted & ungrafted) patients (5.5 vs 2.7 days; p=0.07).</p> <p>Proportion of children with a positive burn wound swab was 39% with ACTICOAT Dressing versus 64% with BIOBRANE Dressing (p=NS).</p>

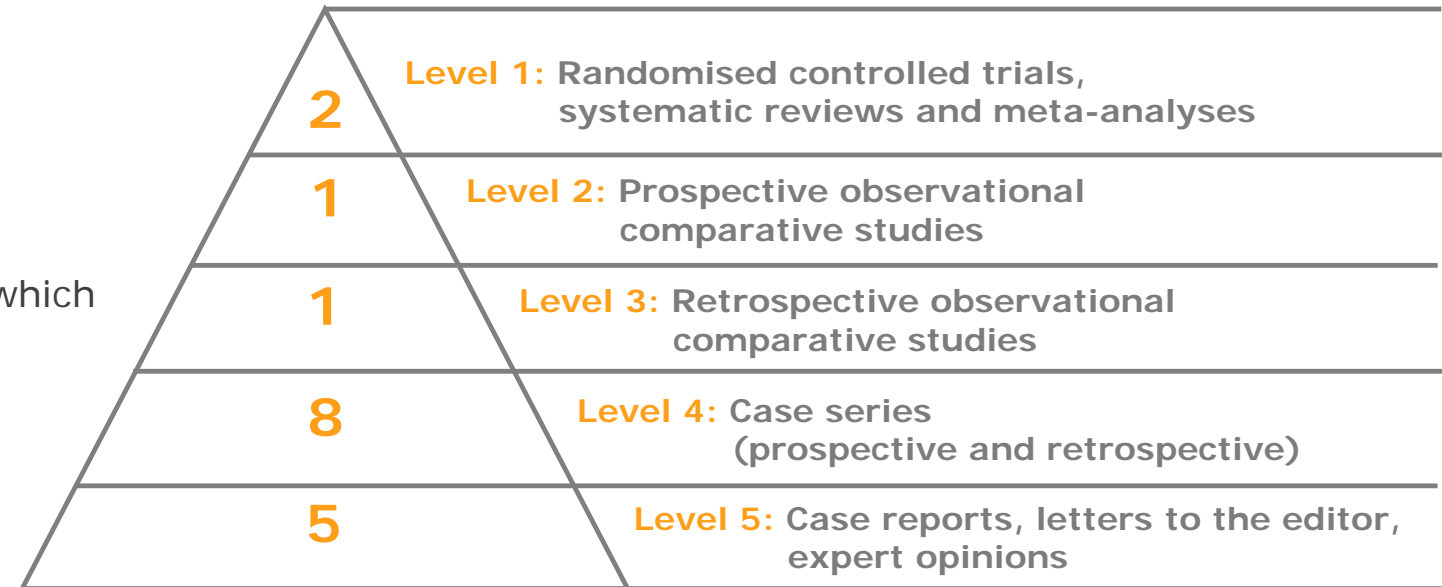
Author (icons link to other sections)	Evidence level	Study overview	Key outcomes / conclusions
Vlachou E, et al. <i>Burns</i> . 2007; 33(8): 979–985. ³¹ 	Level 4	<ul style="list-style-type: none"> • Cohort / Case-controlled study • 30 patients with deep partial-thickness or full-thickness burns of minimum 2% TBSA, requiring autografting • ACTICOAT[◊] Dressing and ACTICOAT[◊] 7 Dressing 	<p>Serum silver levels for ACTICOAT Dressing patients were less than the maximum level reported in the literature for patients treated with SSD cream.</p> <p>This study confirmed the safety of ACTICOAT Dressings for use on burns as a standard part of treatment at this centre.</p>
Cheng E, et al. <i>Australian & New Zealand Burn Association Annual Scientific Meeting</i> . 2004. ³² 	Other	<ul style="list-style-type: none"> • Cost effectiveness analysis • 447 paediatric patients • Mean TBSA was 2.5 to 3.0% • Standard ACTICOAT Dressing (n=241) versus Silvazine™ (n=206) 	<p>Skin graft rate (need for skin graft) was lower with ACTICOAT Dressing than Silvazine™ (15 vs 27%; p=0.001).</p>
Malic C, et al. <i>Plast Surg</i> . 2014; 22(2): 99–102. ³³ 	Other	<ul style="list-style-type: none"> • Cost analysis of six studies • Paediatric scald burns • Mean TBSA was 6.3–6.8% • ACTICOAT Dressing (n=709) versus SSD (n=538) 	<p>Mean time to healing (14.9 vs 17.2 days) and mean LOS (5.9 vs 14.9 days) were shorter with ACTICOAT Dressing than SSD. Dressing changes were less frequent with ACTICOAT Dressing than with SSD (twice per week vs 1.5 times per day).</p> <p>The authors stated that overall health care value was optimised when ACTICOAT Dressing is used for the treatment of paediatric scalds.</p>
Nherera L, et al. <i>Wounds</i> . 2018; 30(6): 160–167. ⁴ 	Other	<ul style="list-style-type: none"> • Cost effectiveness analysis • Partial-thickness burns (1,873 patients) • Mean TBSA <20% • ACTICOAT Dressing versus Aquacel™ Ag versus Mepilex™ Ag versus SSD • US payer perspective 	<p>Supports clinical evidence showing greater reductions in infection rates, LOS, and surgical procedures in favour of ACTICOAT Dressings when compared with other silver delivery systems included in the analysis.</p>



This section summarises key studies supporting the use of ACTICOAT[◇] Antimicrobial Dressings in **chronic wounds**.

Studies that are included elsewhere in the evidence compendium can be identified by navigation icons, which link to the relevant sections.

Evidence pyramid



Information correct up to: 30 March 2020




Author (icons link to other sections)	Evidence level	Study overview	Key outcomes / conclusions
Miller CN, et al. <i>Wound Repair Regen.</i> 2010; 18: 359–367. ³⁴	Level 1	<ul style="list-style-type: none"> • RCT • 12 weeks • 281 community patients with leg ulcers with high bacterial burden • ACTICOAT[◇] Dressing and IODOSORB[◇] 0.9% Cadexomer Iodine Ointment 	<p>Number of wounds healed was 64% with ACTICOAT Dressing and 63% with IODOSORB Ointment.</p> <p>Mean wound healing rates were similar for ACTICOAT Dressing (2.10±1.89) and IODOSORB Ointment (1.69±2.46).</p> <p>In the first 2 weeks of treatment, ACTICOAT Dressing had a significantly higher healing rate compared with IODOSORB Ointment (p<0.01).</p>
Miller CN, et al. <i>Int Wound J.</i> 2011; 8(1): 45–55. ³⁵	Level 1	<ul style="list-style-type: none"> • RCT • Patients with chronic lower leg ulcers • ACTICOAT Dressing versus IODOSORB Ointment • 140 treated with ACTICOAT Dressing, 141 treated with IODOSORB Ointment 	<p>51.4% of swabs collected after baseline had no bacterial growth, 84.7% had no leukocyte growth; 90% of positive swabs yielded <i>S. aureus</i>.</p> <p>Where moderate-to-heavy growth was identified, healing rates were similar for ACTICOAT Dressing and IODOSORB Ointment.</p> <p>Where there was no or low bacterial growth, ACTICOAT Dressing had a significantly faster healing rate compared to IODOSORB Ointment for the growth of leukocytes (p<0.01), gram positive <i>bacilli</i> (p<0.05), gram positive <i>cocci</i> (p<0.010) and gram negative <i>cocci</i> (p<0.05) within 2 weeks.</p>
Gago M, et al. <i>Wounds.</i> 2008; 20(10): 273–278. ²	Level 2	<ul style="list-style-type: none"> • Comparative cohort study • 75 patients with infected chronic wounds (leg ulcers, pressure ulcers, DFUs and post-traumatic ulcers) • ACTICOAT Dressing versus Aquacel[™] Ag and Comfeel[™]/Biatain[™] Silver 	<p>ACTICOAT Dressing was significantly more effective in resolving clinical signs of infection than Aquacel[™] Ag and Comfeel[™]/Biatain[™] Silver (2 weeks with ACTICOAT Dressing vs 4 weeks in both other groups; p<0.05).</p> <p>After 2 weeks, resolution of clinical signs of infection was greater with standard ACTICOAT Dressing than with Aquacel[™] Ag and Comfeel[™]/Biatain[™] Silver (60 vs <10%).</p> <p>Patients in the standard ACTICOAT Dressing group healed significantly faster than both Aquacel[™] Ag (p=0.027) and Comfeel[™]/Biatain[™] Silver (p=0.042) patients.</p> <p>After 8 weeks of treatment more ACTICOAT Dressing patients had healed (56%) than those receiving Aquacel[™] Ag (28%) and Comfeel[™]/Biatain[™] Silver (24%).</p>






Chronic wounds




Author (icons link to other sections)	Evidence level	Study overview	Key outcomes / conclusions
Pajardi G, et al. <i>Int Wound J.</i> 2016; 13(1): 44–52. ³⁶	Level 3	<ul style="list-style-type: none"> Retrospective case series Chronic wounds (mostly venous and arterial ulcers) ACTICOAT[◇] Dressing with Laserskin™ or with Hyalograft 3D™ (n=30) 	Wound dimensions at assessment after cultivated cell treatment improved by 51.3% at 40 days and by 78.5% at end of follow-up (mean baseline value was 39.2); p<0.001 at both timepoints. Wound healing rate was 60% at final follow-up.
Forner-Cordero I, et al. <i>J Wound Care.</i> 2007; 16(5): 235–239. ³⁷	Level 4	<ul style="list-style-type: none"> Case series ACTICOAT Dressing 8 patients with chronic lower limb ulcers and lymphoedema 	All ulcers were healed within 1–9 weeks of treatment. Mean healing time was 26.6 days.
Giovannini UM. Presentation at the 2nd WUWHS, 8-13 July, 2004; Paris, France. <i>Wound Repair Regen.</i> 2005; 13(3): A49-87. ³⁸ 	Level 4	<ul style="list-style-type: none"> Prospective case series Chronic colonized wounds (3 PUs, 1 tropical leg ulcer, 2 VLU, 2 acute foot lesions and 1 chronic foot lesion) ACTICOAT[◇] 7 Dressing with V.A.C.™ n=9 	Erythema of wound edges and exudate both decreased. Swabs showed a decrease in wound surface bacterial load. Within 14–21 days, the wound bed appeared clean and healthy granulation tissue was present in all wounds and all wounds healed. The authors stated that the use of ACTICOAT 7 Dressing with V.A.C.™ was effective in the management of infection.





Author (icons link to other sections)	Evidence level	Study overview	Key outcomes / conclusions
Ivins N, et al. Poster presented at the 27th ACSASWC. 20-23 October 2012, Las Vegas, NV, USA. ³⁹	Level 4	<ul style="list-style-type: none"> • Prospective case series • Mostly venous or mixed disease ulcers (n=20) plus various other wounds (burns, surgical wounds and graft sites) • ACTICOAT[◊] FLEX 3 Dressing • n=31 	<p>Significant reduction in clinical signs of infection at treatment discontinuation with ACTICOAT FLEX 3 compared with baseline (26.7%; p=0.005).</p> <p>Significant reductions in wound area (4.1cm²) and depth (1mm) from baseline to treatment discontinuation (both p=0.003).</p> <p>Non-viable tissue reduced from 40% at baseline to 15% at treatment discontinuation.</p>
Pearce FB, et al. <i>Wound Medicine</i> . 2014; 7: 18–23. ⁴⁰  	Level 4	<ul style="list-style-type: none"> • Retrospective comparative cost analysis • Bilateral axillary hidradenitis skin excision with split thickness skin grafting (n=7) • After excision ACTICOAT[◊] Dressing was applied with NPWT, followed by NPWT alone • After grafting N-Terface[®] and ACTICOAT Dressing were used as overlay 	<p>Mean LOS was 8.7 days.</p> <p>Despite small areas of failed graft take, no patients in the study required any additional grafting procedures for graft loss.</p>
Sibbald RG, et al. <i>Ostomy Wound Management</i> . 2001; 47(10): 38–43. ⁴¹	Level 4	<ul style="list-style-type: none"> • Prospective case series • Chronic non-healing wounds (6 VLU, 2 PUs, 9 foot ulcers, 12 miscellaneous wounds) • ACTICOAT Dressing • n=29 	<p>Four of 6 VLUs decreased in size and exudate levels at week 6. Six of 9 foot ulcers improved.</p> <p>Exudate and wound surface improved, even wounds with deep infection.</p> <p>All PU patients showed decreases in exudate and wound size. All miscellaneous wounds had decreased exudate and wound size. One patient healed.</p>
Sibbald RG, et al. <i>Adv Skin Wound Care</i> . 2007; 20(10): 549–558. ⁴² 	Level 4	<ul style="list-style-type: none"> • Case-controlled study • 15 patients with VLUs • ACTICOAT[◊] 7 Dressing under compression • Serum samples were obtained at baseline, 4 weeks, 8 weeks and final assessment (43 samples; 11 patients) 	<p>Four ulcers healed with a mean time to healing of 9.4 weeks. Median reduction in wound area was 83.5%.</p> <p>Significant reduction in log₁₀ bacterial count between baseline and final biopsies with use of ACTICOAT Dressing (p=0.011).</p> <p>The authors commented that the antimicrobial effects of the ACTICOAT Dressing reduced bacterial burden for healing to begin.</p>



Author (icons link to other sections)	Evidence level	Study overview	Key outcomes / conclusions
Strohal R, et al. <i>J Hosp Infect.</i> 2005; 60: 226–230. ⁴³ 	Level 4	<ul style="list-style-type: none"> • Case-controlled study • ACTICOAT[◊] Dressing • 7 patients with 10 MRSA-colonised wounds (1 DFU, 2 VLU, 1 cicatricial ulcer, 1 trauma ulcer to the head, 1 atopic dermatitis, 1 CREST syndrome, 1 peripheral arterial occlusive disease) • At each dressing change (after 1, 24, 48 and 72 hours) swabs were taken from the upper side of the dressing and the wound bed 	<p>None of the dressings showed heavy MRSA load (+++) breakthrough on the upper side over 72 hours. No bacterial penetration through the dressing in 7 wounds. Of the remaining 3 wounds, two dressings had a MRSA colonisation (++) and one wound had minor colonisation (+) of the upper side. ACTICOAT Dressings were found to provide a complete, or almost complete, barrier to the penetration/spread of MRSA in 95% of readings. In addition, 67% of all wound observations showed a decrease in the MRSA load with an eradication rate of 11%.</p>
Angirasa AK, et al. <i>Ostomy Wound Manage.</i> 2006; 52(5): 60–64. ⁴⁴	Level 5	<ul style="list-style-type: none"> • Case report (n=1) • Two lower extremity diabetic ulcers • Bioengineered dermal implant with ACTICOAT Dressing with compression 	<p>Throughout treatment, both ulcers demonstrated a marked reduction in area and depth. One ulcer closed completely and the other substantially decreased in area and depth.</p>
Arhi C, et al. <i>J Wound Ostomy Continence Nurs.</i> 2013; 40(1): 101-103. ⁴⁵	Level 5	<ul style="list-style-type: none"> • Case report (n=1) • Open abdominal wound with enterocutaneous fistula • ACTICOAT Dressing with gauze and transparent dressing (after discontinuation of NPWT) 	<p>Wound swabs just before discharge showed no significant bacterial growth. At 5 months post-hospital discharge the fistula and the abdominal wound had closed.</p>



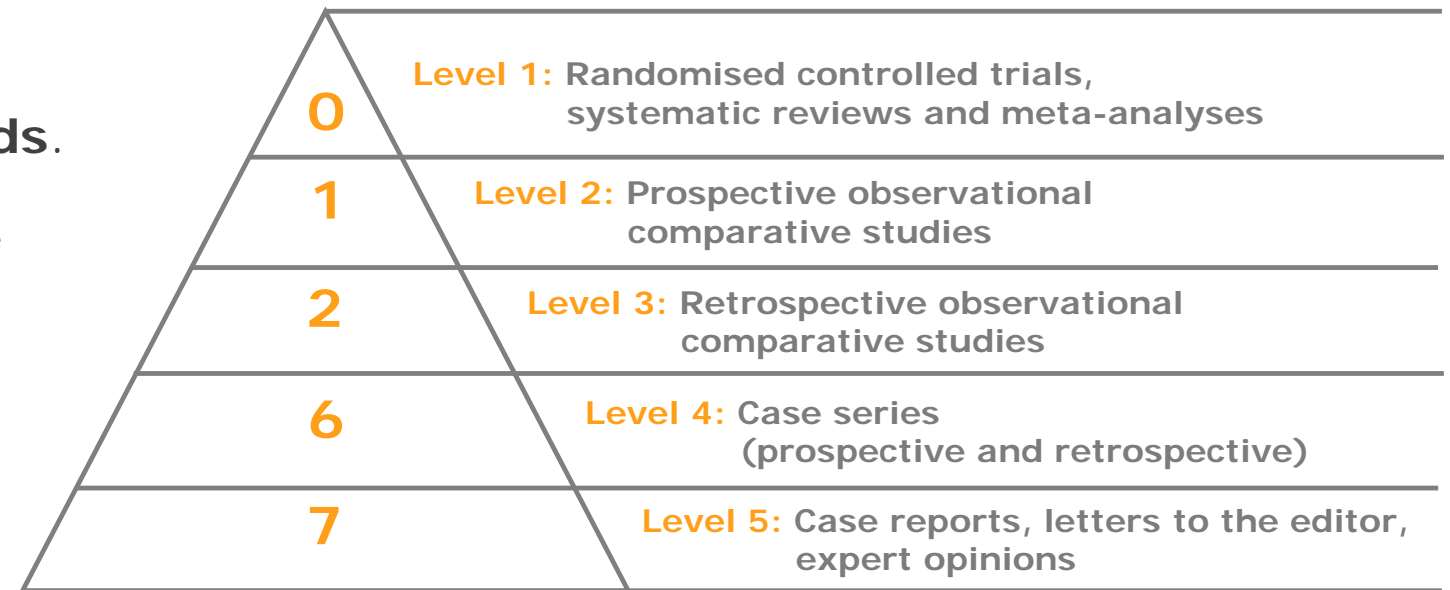
Author (icons link to other sections)	Evidence level	Study overview	Key outcomes / conclusions
Harish V, et al. <i>J Plast Reconstr Aesthet Surg.</i> 2014; 67(7): 1011–1013. ⁴⁶ 	Level 5	<ul style="list-style-type: none"> • Case series (n=2) • Soft tissue necrosis (secondary to cryoglobulinaemia) • ACTICOAT[◇] Dressing with V.A.C.[™] 	<p>The first patient demonstrated no clinical signs of local or systemic infection prior to the dressing change. Cultures remained negative. The dressing was removed at Day 14 and a vascularised neodermis was noted.</p> <p>The second patient remained systemically well prior to the first dressing change at Day 14 and cultures of fluid obtained from the V.A.C.[™] tubing system at each canister change remained negative. A vascularised neodermis was noted at dressing change.</p>
Richards AJ, et al. <i>Int Wound J.</i> 2011; 8(6): 608–611. ⁴⁷ 	Level 5	<ul style="list-style-type: none"> • Case report (n=1) • Breast abscess • ACTICOAT[◇] FLEX Dressing with RENASYS[◇] GO tNPWT 	<p>Full epithelisation of chronic, complex infected breast disease (abscess cavity) was achieved.</p>
Wong S, et al. <i>Medical J Malaysia.</i> 2017; 72: 31–317. ⁴⁸	Level 5	<ul style="list-style-type: none"> • Case report (n=1) • Fungating arm wound • ACTICOAT[◇] FLEX 3 Dressing 	<p>The wound contracted and closed after 2 months of treatment.</p>



This section summarises key studies supporting the use of ACTICOAT[◇] Antimicrobial Dressings in **acute wounds**.

Studies that are included elsewhere in the evidence compendium can be identified by navigation icons, which link to the relevant sections.

Evidence pyramid



Information correct up to: 30 March 2020

One more published study that that is classified as 'other' evidence.






Author (icons link to other sections)	Evidence level	Study overview	Key outcomes / conclusions
Doshi J, et al. <i>J Laryngol Otol.</i> 2006; 120(10):842–844. ⁴⁹	Level 2	<ul style="list-style-type: none"> • Prospective cohort • Bone-anchored hearing aid implantation • ACTICOAT[◊] 7 Dressing + ALLEVYN[◊] Wound Dressing (n=63), ALLEVYN Wound Dressing (n=66), Mepitel[™] (n=10), tri-actocortyl soaked gauze (n=19) 	<p>Infection rates were lower for ACTICOAT 7 Dressing + ALLEVYN Wound Dressing (5.5%), than for ALLEVYN Dressing (10.3%), Mepitel[™] (50.0%) and tri-actocortyl soaked gauze (15.8%).</p> <p>Mean additional post-operative visits to the clinic were also lower with ACTICOAT 7 Dressing + ALLEVYN Dressing (0.4) than other dressings ALLEVYN (1), Mepitel[™] (3.7) and tri-actocortyl soaked gauze (1.5). The authors stated that ACTICOAT 7 Dressing + ALLEVYN Wound Dressing is the treatment of choice for their bone anchored hearing aid program.</p>
Narayan P, et al. <i>Child's Nervous System.</i> 2014; 30(11): 1953. ⁵⁰	Level 3	<ul style="list-style-type: none"> • Retrospective cohort • Neurosurgery • ACTICOAT[◊] Dressing (n=284) versus standard dressings (n=224) 	<p>Surgical site infection rate was lower with ACTICOAT Dressing than standard dressings (2.1 vs 4.4%; p=NS). Cerebrospinal fluid shunt infection was significantly lower with ACTICOAT Dressing than standard dressings (1.4 vs 7.4%; p=0.03).</p>
Harris J. <i>Am J Infect Control.</i> 2012; 40(5):e195–e196. Presentation 125. ⁵¹	Level 3	<ul style="list-style-type: none"> • Retrospective cohort • Caesarean section • ACTICOAT[◊] FLEX 7 Dressing (with PICO sNPWT in high-risk patients during 2012) introduced in 2011 as part of an infection prevention program versus prior standard care 	<p>Overall, a 96% reduction in infections from 2007 to 2012. A reduction from 6 to 1 SSI after introduction of ACTICOAT FLEX 7 Dressing in 2011.</p>
Hickson E, et al. <i>Surg Infect.</i> 2015; 16: 174–177. ⁵²	Level 3	<ul style="list-style-type: none"> • Retrospective analysis • Chart review of 4,942 caesarean deliveries from 2007 to 2012 • Incremental interventions for low- and high-risk patients in 2011 • Post-operative ACTICOAT Dressing and incisional NPWT in 2012 	<p>The incidence of SSIs was reduced from 2.13% in 2007 to 0.10% in 2012 (95% relative reduction; p<0.0001). No substantial changes in the patient risk factors over this time. Implementation of the bundle in 2011, including ACTICOAT Dressing, resulted in a total of 92 caesarean post-operative SSIs avoided.</p>





Acute wounds







Author (icons link to other sections)	Evidence level	Study overview	Key outcomes / conclusions
Carnali M, et al. <i>Acta Vulnologica</i> . 2016; 14(1):24-39. ⁵³ 	Level 4	<ul style="list-style-type: none"> Retrospective case series Open or dehisced surgical wounds (pilonidal cysts) NPWT (with ACTICOAT[◇] FLEX 3 Dressing when dehiscence was due to sepsis) Open surgery (n=61), dehiscence (n=35) 	All patients healed within 40–45 days without relapsing infections.
Choi WW, et al. <i>Pediatr Surg Int</i> . 2011; 27(8):907-911. ⁵⁴ 	Level 4	<ul style="list-style-type: none"> Retrospective case series Gastroschisis RENASYS[◇] tNPWT with ACTICOAT[◇] 7 Dressing n=4 	All wounds contracted substantially with some or near-complete epithelialisation. In one case, after 14 days the wound had contracted significantly with near-complete epithelialisation. NPWT was then stopped and ACTICOAT 7 Dressing treatment continued and LOS was 22 days.
Dunn RM, et al. <i>Eplasty</i> . 2011; 11:e14. ⁵⁵ 	Level 4	<ul style="list-style-type: none"> Prospective case series Split thickness skin grafts (includes chronic, traumatic, surgical and burns) ACTICOAT[◇] Dressing applied to the graft surface followed by gauze-based NPWT n=21 (postgraft group) 	Median length of time to discontinuation was 5 days at which point 95% of wounds were healed or progressing towards healing. Median rate of graft take was 96% and no wounds required regrafting. Median LOS was 5 days.
Keen JS, et al. <i>Int Wound J</i> . 2012; 9(1):7-13. ⁵⁶	Level 4	<ul style="list-style-type: none"> Retrospective case series Open Gustilo/Anderson type II/III fractures ACTICOAT Dressing n=17 	Mean LOS was 11.8 days. 6 patients had positive cultures, of which 5 were deemed contaminants. One patient with a positive culture went on to develop MRSA infection. 14 of 17 patients healed (82.3%); 3 were lost to follow-up.



Acute wounds





Author (icons link to other sections)	Evidence level	Study overview	Key outcomes / conclusions
Kępa K, et al. <i>Polish Journal of Thoracic and Cardiovascular Surgery</i> 2013; 10(3): 204–210. ⁵⁷  	Level 4	<ul style="list-style-type: none"> Retrospective cohort Surgical wounds (sternotomy) ACTICOAT[◊] FLEX 3 with V.A.C.[™] (group 1: patients with skin and subcutaneous tissue infection, group 2: patients with mediastinitis) n=32 (group 1, n=14; group 2, n=18) 	<p>Mean LOS was 7.5 days.</p> <p>Most commonly isolated organisms were MRSE (<i>S. epidermidis</i>; 26.2%) and <i>P. aeruginosa</i> (21.0%).</p> <p>Concurrent saphenectomy wound infection occurred in 2 patients (6.3%).</p>
Bhattacharyya M, et al. <i>Int J Low Extrem Wounds</i> . 2006; 5: 105–108. ⁵⁸ 	Level 5	<ul style="list-style-type: none"> Case study (n=1) ACTICOAT[◊] Dressing Ongoing wound infection caused by MRSA and beta-haemolytic streptococcus following complex knee surgery 	<p>Antibiotics were unable to resolve persistent superficial infection at the wound site.</p> <p>A subsequent regime of irrigation of the wound, and application of ACTICOAT Dressing secured with OPSITE[◊] Dressings reduced exudate. Healthy granulation tissue developed leading to complete healing with no recurrence in the infection at 3 years post-surgery follow up.</p> <p>The author suggests that continuous bactericidal activity negated the need for frequent hospital admissions for systemic antibiotic treatment.</p>
Bhattacharyya M, et al. <i>Int J Low Extrem Wounds</i> 2008; 7: 45–48. ⁵⁹ 	Level 5	<ul style="list-style-type: none"> Case studies (n=2) Use of ACTICOAT[◊] 7 following knee surgery revision to help avoid skin grafting 	<p>Two patients were successfully treated, without using systemic antimicrobials, after developing MRSA infection in the surgical site. Successful bacterial clearance helped to reduce the spread of cutaneous infection and subsequent wound necrosis without the use of systemic antibiotics.</p>
Kimble R, et al. <i>Letter to the Editor</i> . 2015. DOI: 10.13134/RG.2.1.4363.9200. ⁶⁰	Level 5	<ul style="list-style-type: none"> Case study (n=1) Pyoderma gangrenosum ACTICOAT Dressing 	<p>After 2 days the area was less inflamed and had reduced in depth. Re-epithelialisation occurred at 14 days.</p>



Acute wounds



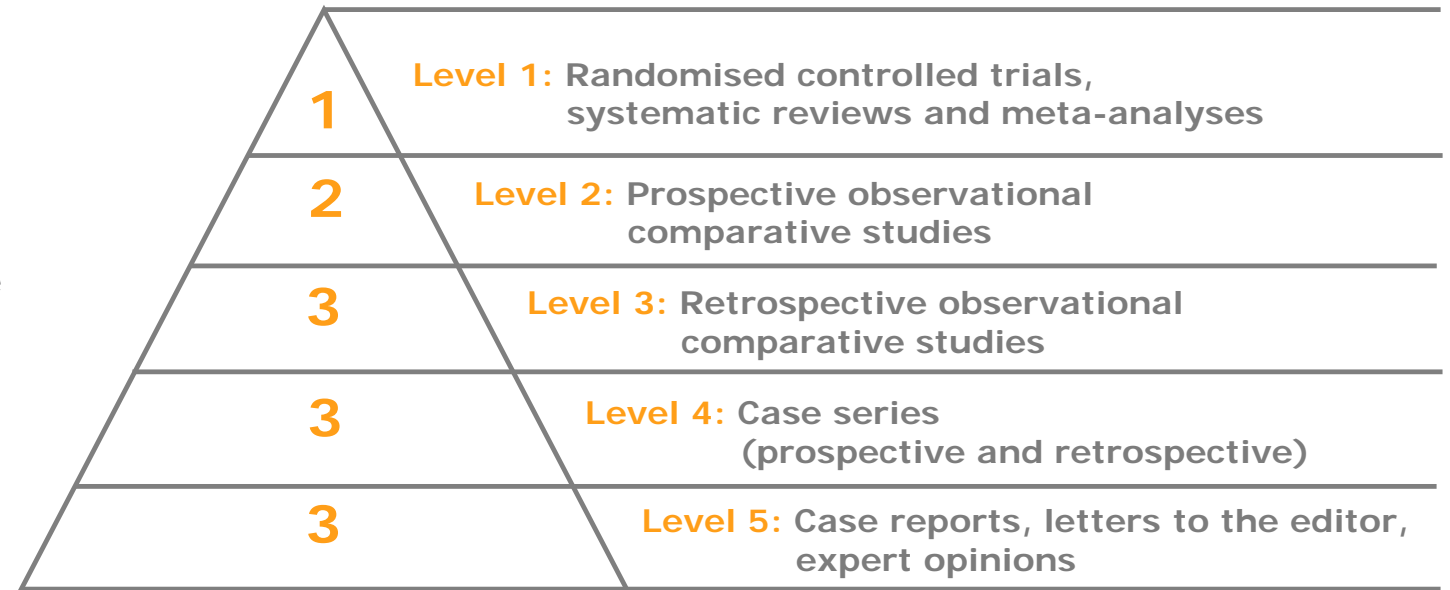
Author (icons link to other sections)	Evidence level	Study overview	Key outcomes / conclusions
Riordan NH, et al. <i>J Transl Med.</i> 2015;13:242. ⁶¹	Level 5	<ul style="list-style-type: none"> • Case report (n=1) • Surgical ulcer • Alpha patches with ACTICOAT[◇] Dressing 	At the 10-week follow-up visit the ulcer had completely healed.
Sakata S, et al. <i>Pediatr Surg Int.</i> 2009;25(1):117–119. ⁶² 	Level 5	<ul style="list-style-type: none"> • Case report (n=1) • Neonatal necrotising fasciitis • ACTICOAT[◇] 7 Dressing under V.A.C.[™] 	The infant recovered well from skin graft surgery and was eventually discharged from hospital after 4 weeks.
Sharp E. <i>J Wound Care.</i> 2013;22(10 Suppl):S5–9. ⁶³ 	Level 5	<ul style="list-style-type: none"> • Case report (n=1) • Surgical and trauma wounds • ACTICOAT[◇] FLEX 7 Dressing with PICO[◇] sNPWT (for 7 days) • Total study population n=8 	<p>A reduction in wound cavity diameter from 2cm to 1.5cm was noted in the first 7 days.</p> <p>The patient received 3 weeks of NPWT, which resulted in full healing and resolution of the infection.</p>
Zhou K, et al. <i>Ostomy Wound Manage.</i> 2015;61(7):32–37. ⁶⁴	Level 5	<ul style="list-style-type: none"> • Case report (n=1) • Dehisced hand wound • ACTICOAT Dressing + ALLEVYN[◇] GENTLE BORDER Dressing + Medigrip[™] 	<p>Wound size, odour and drainage decreased after 1 week.</p> <p>The wound closed after 35 days of treatment.</p>
Wright JB, et al. <i>Wounds.</i> 2003;15(5):132–144. ⁶⁵	Other	<ul style="list-style-type: none"> • Preclinical study • ACTICOAT 7 Dressing versus gauze impregnated with PHMB • <i>In vitro</i> and <i>in vivo</i> studies (porcine wound models) 	<p>Both dressings had potent <i>in vitro</i> bactericidal effects; however, in zone of inhibition tests PHMB did not have activity beyond its borders.</p> <p>The three-week <i>in vivo</i> experiments demonstrated that wounds dressed with ACTICOAT 7 Dressing healed faster (90% of wounds re-epithelialized by Day 18) than those with the PHMB dressing (25% of wounds re-epithelialized by Day 21) and had lower wound bioburden.</p>



This section summarises key studies supporting the use of ACTICOAT[◇] Antimicrobial Dressings in wounds with **antibiotic-resistant organisms**.

Studies that are included elsewhere in the evidence compendium can be identified by navigation icons, which link to the relevant sections.

Evidence pyramid









Information correct up to: 30 March 2020



Antibiotic-resistant organisms









Author (icons link to other sections)	Evidence level	Study overview	Key outcomes / conclusions
Huang Y, et al. <i>Burns</i> . 2007; 33(2): 161–166. ⁸  	Level 1	<ul style="list-style-type: none"> • RCT • 166 wounds (98 patients) • Mean burn size 54.2% TBSA • ACTICOAT[◊] Dressing and SSD 	<p>Bacterial clearance rates (includes MRSA) on days 6 and 12 after application of treatment for ACTICOAT Dressing patients were higher than in SSD patients ($p < 0.05$).</p> <p>Clearance rates were 16.7% (day 6) and 26.7% (day 12) for the ACTICOAT group in contrast with 11.5% and 19.2%, respectively, for the SSD group. Healing time was 3.35 days shorter with ACTICOAT Dressing than SSD (12.42 vs 15.79 days).</p>
Argirova M, et al. Book chapter: <i>Skin Grafts- Indications, Applications and Current Research</i> . 2011: 237–264. ¹⁸  	Level 2	<ul style="list-style-type: none"> • Prospective cohort • Paediatric burns (78 superficial burns, 19 deep burns, 5 excised burns, 5 autografts, 5 donor sites) • Mean TBSA of 7.89% • ACTICOAT Dressing/ACTICOAT[◊] FLEX 3 Dressing/ACTICOAT[◊] FLEX 7 Dressing (n=68) versus SSD (n=43) 	<p>After 4 days, ACTICOAT Dressing reduced bacterial flora from 17.65% to 16.18% compared with an increase from 13.95% to 25.58% for SSD. Isolates of MRSA and <i>P. aeruginosa</i> were reduced at day 12 compared with start of ACTICOAT Dressing treatment. All other bacteria initially identified were not present at day 12.</p> <p>For SSD, MRSA isolates were reduced and <i>Streptococcus beta haemolyticus</i> was cleared. <i>Acinetobacter spp</i> and <i>P. aeruginosa</i> were found in 9% and 7% of cases, respectively, despite not being present before treatment. Hospital stay was shorter with ACTICOAT Dressing than SSD (16.95 vs 26.90 days; $p < 0.01$) as was epithelialisation time (12.98 vs 19.79 days; $p < 0.01$).</p>
Kępa K, et al. <i>Polish Journal of Thoracic and Cardiovascular Surgery</i> 2013; 10(3): 204–210. ⁵⁷  	Level 2	<ul style="list-style-type: none"> • Retrospective cohort • Surgical wounds (sternotomy) • ACTICOAT FLEX 3 Dressing with V.A.C.[™] (group 1: patients with skin and subcutaneous tissue infection, group 2: patients with mediastinitis) • n=32 (group 1, n=14; group 2, n=18) 	<p>Mean LOS was 7.5 days.</p> <p>Most commonly isolated organisms were MRSE (26.2%) and <i>P. aeruginosa</i> (21.0%).</p> <p>Concurrent saphenectomy wound infection occurred in 2 patients (6.3%).</p>



Antibiotic-resistant organisms





Author (icons link to other sections)	Evidence level	Study overview	Key outcomes / conclusions
Fong J, et al. <i>Burns</i>. 2005; 31(5): 562–567.²²  	Level 3	<ul style="list-style-type: none"> • Cohort study • All burns patients (superficial to deep partial thickness) • Mean TBSA was 9.0–9.5% • Audit comparing ACTICOAT[◊] Dressing (19 patients) with Silvazine[™] (51 patients) 	<p>A reduction in the incidence of burn wound cellulitis for ACTICOAT Dressing compared with Silvazine[™] (10.5 vs 55.0%).</p> <p>Antibiotic usage was reduced with ACTICOAT Dressing compared with Silvazine[™] (5.2 vs 57.0%).</p>
Glik J, et al. <i>Int Wound J</i>. 2018; 15(3): 344–349.³  	Level 3	<ul style="list-style-type: none"> • Retrospective case series • Burns • Silver dressings (ACTICOAT Dressing / ACTICOAT[◊] FLEX 3 Dressing) and antiseptics versus antibiotics and antimycotics • n=2,000 • Implementation of a new management strategy in 2015 	<p>The number of sepsis cases decreased from 60 in 2014 to 46 in 2016, with a decrease in cases caused by <i>P. aeruginosa</i> (12 cases in 2014 and 1 case in 2016).</p> <p>Sensitivity to most antibiotics used to treat <i>P. aeruginosa</i> infections increased in 2016.</p>
Strand O, et al. <i>Ann Burns Fire Disasters</i>. 2010; 23(4): 182–185.²³ 	Level 3	<ul style="list-style-type: none"> • Retrospective case review • Paediatric burns patients (mostly water and flames) • Mean TBSA was 5.74 to 5.97% • Before (2001) and after (2004 and 2007) implementation of a new care protocol • ACTICOAT Dressing, INTRASITE[◊] GEL Dressing and ALLEVYN[◊] ADHESIVE Dressing • In 2001, 292 paediatric burn patients (48 in-patients); in 2004, 371 patients (69 in-patients); in 2007, 397 patients (57 in patients) 	<p>Reduction in antibiotic usage (from 70 to 25%; p<0.001).</p>
Tonkin C, et al. <i>Primary Intention</i>. 2005; 13(4): 163–168.²⁴ 	Level 3	<ul style="list-style-type: none"> • Cohort study • Four periodic clinical audits • Burns patients (mostly flame; no full thickness burns) • Mean TBSA was 9.3% • ACTICOAT Dressing (n=36) versus SSD (n=36) 	<p>Antibiotic usage was significantly lower in the ACTICOAT Dressing group compared with the SSD group (11.1 vs 61.1%; p=0.016).</p>



Antibiotic-resistant organisms





Author (icons link to other sections)	Evidence level	Study overview	Key outcomes / conclusions
Strohal R, et al. <i>J Hosp Infect.</i> 2005;60:226–230. ⁴³ 	Level 4	<ul style="list-style-type: none"> • Case-controlled study • ACTICOAT[◊] Dressing • 7 patients with 10 MRSA-colonised wounds (1 DFU, 2 VLU, 1 cicatricial ulcer, 1 trauma ulcer to the head, 1 atopic dermatitis, 1 CREST syndrome, 1 peripheral arterial occlusive disease) • At each dressing change (after 1, 24, 48 and 72 hours) swabs were taken from the upper side of the dressing and the wound bed 	<p>No dressings showed heavy MRSA load (+++) breakthrough on the upper side over 72 hours; there was no bacterial penetration through the dressing in 7 wounds. Of the remaining 3 wounds, two dressings had MRSA colonisation (++) and one wound had minor colonisation (+) of the upper side.</p> <p>ACTICOAT Dressings provided a complete, or almost complete, barrier to the penetration/spread of MRSA in 95% of readings.</p> <p>In addition, 67% of all wound observations showed a decrease in MRSA load with an eradication rate of 11%.</p>
Newton H. <i>Wounds UK.</i> 2010;6:56–65. ⁶⁶	Level 4	<ul style="list-style-type: none"> • Case series (n=12) • Care bundle implementation • ACTICOAT Dressing + aseptic no-touch technique 	<p>Reduced MRSA-associated bacteraemia (wound origin).</p>
Bhattacharyya M, et al. <i>Int J Low Extrem Wounds.</i> 2006;5:105–108. ⁵⁸ 	Level 5	<ul style="list-style-type: none"> • Case study (n=1) • ACTICOAT Dressing • Ongoing wound infection caused by MRSA and beta-haemolytic streptococcus following complex knee surgery 	<p>Antibiotics were unable to resolve persistent superficial infection at the wound site. A subsequent regime of irrigation of the wound, and application of ACTICOAT Dressing secured with OPSITE[◊] Dressings reduced exudate. Healthy granulation tissue developed leading to complete healing with no recurrence in the infection at 3 years post-surgery follow up.</p> <p>The author suggests that continuous bactericidal activity negated the need for frequent hospital admissions for systemic antibiotic treatment.</p>



Antibiotic-resistant organisms



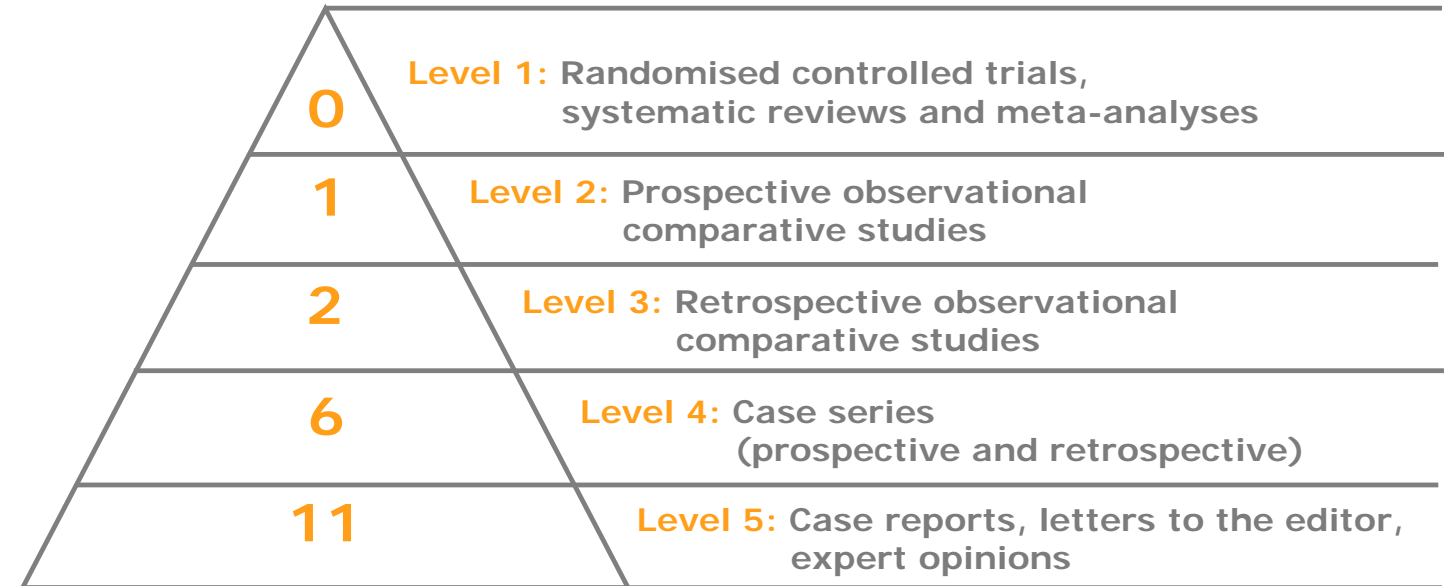
Author (icons link to other sections)	Evidence level	Study overview	Key outcomes / conclusions
Bhattacharyya M, et al. <i>Int J Low Extrem Wounds</i> 2008; 7: 45–48. ⁵⁹ 	Level 5	<ul style="list-style-type: none"> • Case studies (n=2) • Use of ACTICOAT[◇] 7 Dressing following knee surgery revision to help avoid skin grafting 	<p>Two patients were successfully treated, without using systemic antimicrobials, after developing MRSA infection in the surgical site.</p> <p>Successful bacterial clearance helped to reduce the spread of cutaneous infection and subsequent wound necrosis without the use of systemic antibiotics.</p>
Pour SM. <i>J Wound Ostomy Continence Nurs.</i> 2011; 38(4): 449–452. ⁶⁷ 	Level 5	<ul style="list-style-type: none"> • Case study (n=1) • 56-year-old man with necrotising fasciitis (Fournier’s gangrene) and signs of cellulitis • Extensive surgical debridement on day of admission prior to reconstruction • NPWT with ACTICOAT[◇] Dressing used 	<p>The infections resolved with treatment and NPWT with ACTICOAT Dressing promoted wound healing and provided a solid matrix for surgical reconstruction.</p>



This section summarises key studies supporting the use of ACTICOAT[◇] Antimicrobial Dressings **with NPWT**.

Studies that are included elsewhere in the evidence compendium can be identified by navigation icons, which link to the relevant sections.

Evidence pyramid







Information correct up to: 30 March 2020



Use with NPWT







Author (icons link to other sections)	Evidence level	Study overview	Key outcomes / conclusions
Harris J. <i>Am J Infect Control.</i> 2012;40(5):e195–e196. Presentation 125. ⁵¹  	Level 3	<ul style="list-style-type: none"> Retrospective cohort Caesarean section ACTICOAT[◇] FLEX 7 Dressing (with PICO[◇] sNPWT in high-risk patients during 2012) introduced in 2011 as part of an infection prevention program versus prior standard of care 	<p>Overall, a 96% reduction in infections from 2007 to 2012. A reduction from 6 to 1 SSI after introduction of ACTICOAT FLEX 7 Dressing in 2011.</p>
Hickson E, et al. <i>Surg Infect.</i> 2015;16:174–177. ⁵²  	Level 3	<ul style="list-style-type: none"> Retrospective analysis Chart review of 4,942 caesarean deliveries from 2007 to 2012 Incremental interventions for low- and high-risk patients in 2011 Post-operative ACTICOAT[◇] Dressing and incisional NPWT in 2012 	<p>Incidence of SSIs was reduced from 2.13% in 2007 to 0.10% in 2012 (95% relative reduction; p<0.0001). No substantial changes in the patient population risk factors over this time. Implementation of the bundle in 2011, including ACTICOAT Dressing, resulted in a total of 92 caesarean post-operative SSIs avoided.</p>
Hurd T, et al. <i>Adv Wound Care.</i> 2017;6:33–37. ⁶⁸	Level 3	<ul style="list-style-type: none"> Retrospective analysis 1,107 patients treated with tNPWT (RENASYS[◇] tNPWT and V.A.C.[™]) in a community setting in Canada 34% received NPWT in combination with ACTICOAT[◇] FLEX 3 Dressing (wounds with suspected localised bacteria burden or localized infection) 	<p>A sub-analysis of patients who received ACTICOAT FLEX 3 Dressing found that more than 90% achieved their treatment goal and had a similar weekly reduction in wound healing whether using RENASYS tNPWT or V.A.C.[™] NPWT systems (63.9% and 68.2%, respectively).</p>







Use with NPWT



Author (icons link to other sections)	Evidence level	Study overview	Key outcomes / conclusions
Carnali M, et al. <i>Acta Vulnologica</i> . 2016;14(1):24–39. ⁵³ 	Level 4	<ul style="list-style-type: none"> Retrospective case series Open or dehisced surgical wounds (pilonidal cysts) NPWT (with ACTICOAT[◊] FLEX 3 Dressing when dehiscence was due to sepsis) Open surgery (n=61), wound dehiscence (n=35) 	All patients healed within 40–45 days without relapsing infections.
Choi WW, et al. <i>Pediatr Surg Int</i> . 2011;27(8):907–911. ⁵⁴ 	Level 4	<ul style="list-style-type: none"> Retrospective case series Gastroschisis RENASYS[◊] tNPWT with ACTICOAT[◊] 7 Dressing n=4 	<p>All wounds contracted substantially with some or near-complete epithelialisation.</p> <p>In one case, after 14 days the wound had contracted significantly with near-complete epithelialisation. NPWT was stopped and ACTICOAT 7 Dressing treatment continued and LOS was 22 days.</p>
Dunn RM, et al. <i>Eplasty</i> . 2011;11:e14. ⁵⁵ 	Level 4	<ul style="list-style-type: none"> Prospective case series Split thickness skin grafts (includes chronic, traumatic, surgical and burns) ACTICOAT[◊] Dressing applied to the graft surface followed by gauze-based NPWT n=21 (postgraft group) 	<p>Median length of time to discontinuation was 5 days at which point 95% of wounds were healed or progressing towards healing.</p> <p>Median rate of graft take was 96% and no wounds required regrafting.</p> <p>Median LOS was 5 days.</p>
Giovannini UM. Presentation at the 2nd WUWHS, 8-13 July, 2004; Paris, France. <i>Wound Repair Regen</i> . 2005;13(3):A49-87. ³⁸ 	Level 4	<ul style="list-style-type: none"> Prospective case series Chronic colonized wounds (3 PUs, 1 tropical leg ulcer, 2 VLU, 2 acute foot lesions and 1 chronic foot lesion) ACTICOAT 7 Dressing with V.A.C.[™] n=9 	<p>Erythema of wound edges and exudate both decreased. Swabs showed a decrease in wound surface bacterial load. Within 14–21 days, the wound bed appeared clean and healthy granulation tissue was present in all wounds. All wounds healed.</p> <p>The authors stated that the use of ACTICOAT 7 Dressing with V.A.C.[™] was effective in the management of infection.</p>




Author (icons link to other sections)	Evidence level	Study overview	Key outcomes / conclusions
Goldstein JA, et al. <i>J Foot Ankle Surg.</i> 2010;49:513–516. ⁶⁹	Level 4	<ul style="list-style-type: none"> • Case series • Local random flaps for reconstruction of complex ankle wounds • 10 consecutive patients (17 local flaps) were treated postoperatively with NPWT • Incisions and flaps were covered with a non-adhesive silicone layer and ACTICOAT[◊] Dressing 	<p>All flaps healed without tissue compromise or necrosis. Only one partial dehiscence and no infections were observed. No partial or complete flap losses.</p>
Kępa K, et al. <i>Polish Journal of Thoracic & Cardiovascular Surgery.</i> 2013;10(3):204–210. ⁵⁷  	Level 4	<ul style="list-style-type: none"> • Retrospective cohort • Surgical wounds (sternotomy) • ACTICOAT[◊] FLEX 3 Dressing with V.A.C.[™] (group 1: patients with skin and subcutaneous tissue infection, group 2: patients with mediastinitis) • n=32 (group 1, n=14; group 2, n=18) 	<p>Mean LOS was 7.5 days. Most commonly isolated organisms were MRSE (26.2%) and <i>P. aeruginosa</i> (21%). Concurrent saphenectomy wound infection occurred in 2 patients (6.3%).</p>
Pearce FB, et al. <i>Wound Medicine.</i> 2014;7:18–23. ⁴⁰  	Level 4	<ul style="list-style-type: none"> • Retrospective comparative cost analysis • Bilateral axillary hidradenitis skin excision with split thickness skin grafting (n=7) • After excision ACTICOAT[◊] Dressing was applied with NPWT, followed by NPWT alone • After grafting N-Terface[®] and ACTICOAT Dressing were used as overlay 	<p>Mean LOS was 8.7 days. Despite small areas of failed graft take, no patients in the study required any additional grafting procedures for graft loss.</p>
Belek KA, et al. <i>Eplasty.</i> 2010;10:e33. ⁷⁰	Level 5	<ul style="list-style-type: none"> • Case study (n=1) • 31-year-old man, deep laceration to the dominant arm • Microsurgical reconstruction of the brachial artery with a radial artery flow-through flap and a single-stage donor-site closure with an Integra[™] dermal matrix template and split-thickness skin graft meshed under ACTICOAT Dressing was performed 	<p>The authors stated that it is important that both the Integra[™] and the skin graft are meshed under a protective wound layer such as ACTICOAT Dressing to allow for continued fluid removal beneath the grafts as well as improved imbibition of the grafts for improved graft take.</p>



Use with NPWT







Author (icons link to other sections)	Evidence level	Study overview	Key outcomes / conclusions
Chariker M, et al. <i>Eplasty.</i> 2012; 12: e26. ⁷¹	Level 5	<ul style="list-style-type: none"> • Case study (n=1) • One child aged 5 years with soft-tissue cellulitis of the lower ear auricle and adjacent neck • ACTICOAT[◊] Dressing was used as a contact layer for the NPWT dressing 	Successful treatment of a necrotising wound caused by a spider bite using NPWT and ACTICOAT Dressing. The granulation bed appeared to be less hypertrophic than without use of ACTICOAT Dressing.
Forlee M. <i>Wounds International.</i> January 2020. ⁷²	Level 5	<ul style="list-style-type: none"> • Retrospective case series • Chronic and post-surgical wounds • RENASYS[◊] tNPWT with ACTICOAT[◊] FLEX 3 Dressing • n=6 (5 used ACTICOAT FLEX 3 Dressing) 	Signs of infection resolved during combined therapy without the need for further systemic antibiotics. All wounds were progressing towards healing.
González Alaña I, et al. <i>Ann Burns Fire Disasters.</i> 2013; 26: 90–93. ⁷³	Level 5	<ul style="list-style-type: none"> • Case study (n=1) • One patient with major third-degree flame burns to the lower extremities • Combined treatment using Integra[™] and RENASYS[◊] tNPWT • ACTICOAT Dressing used to cover Integra[™] 	Combined treatment using the matrix and NPWT allowed complete coverage of all the affected structures that could not otherwise have been covered by simple skin grafts, with preservation of joint function. RENASYS tNPWT secured stability and adherence of the dermal equivalent to the surgical bed while it eliminated exudate caused by <i>P. aeruginosa</i> infection that would have been detrimental to dermal regeneration template. The authors stated that ACTICOAT Dressing may have been helpful in enabling the matrix product to take despite continuous positive swab cultures.
Harish V, et al. <i>J Plast Reconstr Aesthet Surg.</i> 2014; 67(7): 1011–1013. ⁴⁶ 	Level 5	<ul style="list-style-type: none"> • Case series (n=2) • Necrosis • ACTICOAT Dressing with V.A.C.[™] 	The first patient demonstrated no clinical signs of local or systemic infection prior to the dressing change. Cultures remained negative. The dressing was removed at day 14 showing vascularised neodermis. The second patient remained well prior to the first dressing change at Day 14. Cultures of fluid from the V.A.C. [™] tubing system at each canister change remained negative. Vascularised neodermis was noted at dressing change.



Use with NPWT



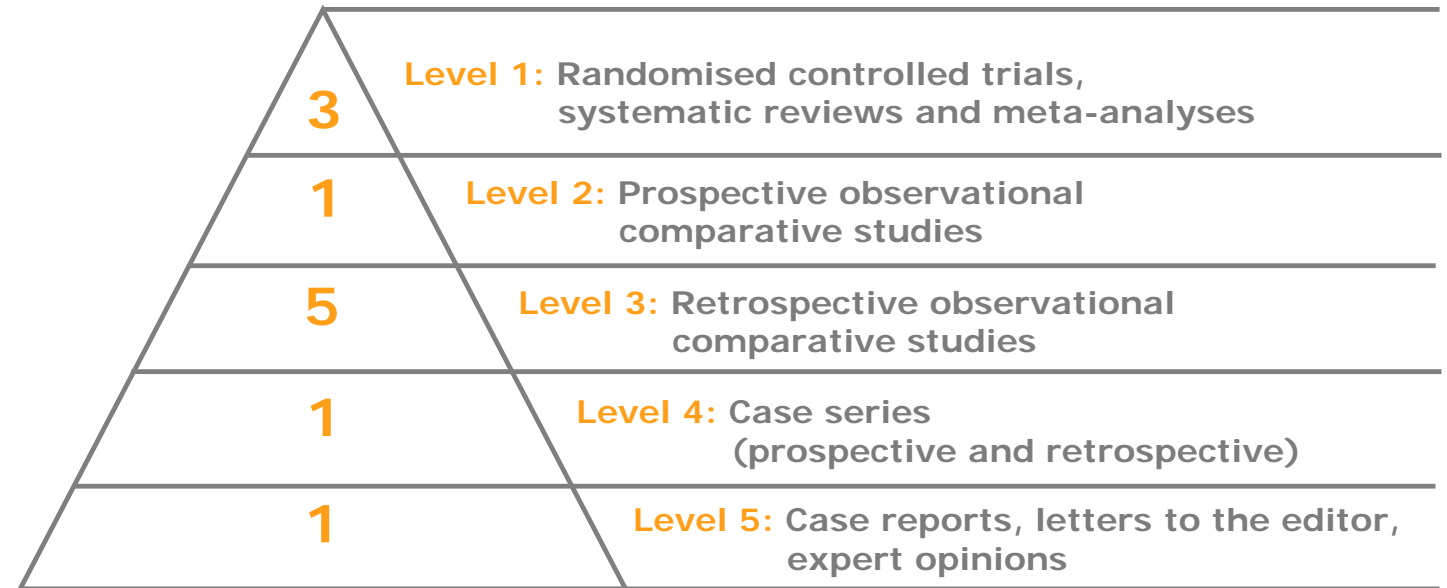
Author (icons link to other sections)	Evidence level	Study overview	Key outcomes / conclusions
Pour SM. <i>J Wound Ostomy Continence Nurs.</i> 2011; 38(4): 449–452. ⁶⁷ 	Level 5	<ul style="list-style-type: none"> • Case study (n=1) • 56-year-old man with necrotising fasciitis • Extensive surgical debridement at admission • NPWT with ACTICOAT[◊] Dressing used 	NPWT with ACTICOAT Dressing promoted wound healing and provided a solid matrix for surgical reconstruction.
Psoinos CM, et al. <i>J Pediatr Surg.</i> 2009; 4: e23–26. ⁷⁴	Level 5	<ul style="list-style-type: none"> • Case study (n=1) • 8-month-old female infant with extensive scald burns to the lower back/buttocks (6% TBSA) • ACTICOAT Dressing was placed between the graft and the NPWT gauze dressing (the outer mesh layer was used) 	<p>The skin graft had 100% take. The child had no complications or limitations from burns or skin grafting procedures 7 months postoperatively. At home there were no signs of infection or other complications. Regained full movement and use of buttock; no pain or restrictions.</p>
Richards AJ, et al. <i>Int Wound J.</i> 2011; 8: 608–611. ⁴⁷ 	Level 5	<ul style="list-style-type: none"> • Case study (n=1) • Breast abscess • ACTICOAT[◊] FLEX Dressing with RENASYS[◊] GO tNPWT 	<p>The combination of ACTICOAT Dressing with NPWT following radical excision was safe and well tolerated. Full epithelialisation of the wound was achieved and there was no recurrence of the infection for the duration of the treatment.</p>
Sakata S, et al. <i>Pediatr Surg Int.</i> 2009; 25(1): 117–119. ⁶² 	Level 5	<ul style="list-style-type: none"> • Case study (n=1) • Neonatal necrotising fasciitis • ACTICOAT[◊] 7 Dressing under V.A.C.[™] 	The infant recovered well from skin graft surgery and was eventually discharged from hospital after 4 weeks.
Sharp E. <i>J Wound Care.</i> 2013; 22(10 Suppl): S5–9. ⁶³ 	Level 5	<ul style="list-style-type: none"> • Case study (n=1) • Surgical and trauma wounds • ACTICOAT[◊] FLEX 7 Dressing with PICO[◊] sNPWT (7 days) • Total study population n=8 	<p>A reduction in wound cavity diameter from 2cm to 1.5cm was noted in the first 7 days. The patient received 3 weeks of NPWT, which resulted in full healing and resolution of the infection.</p>



This section summarises key studies supporting the **cost benefits** of using ACTICOAT[◇] Antimicrobial Dressings.

Studies that are included elsewhere in the evidence compendium can be identified by navigation icons, which link to the relevant sections.




Evidence pyramid








Information correct up to: 30 March 2020

Five more published studies that are classified as 'other' evidence.










Author (icons link to other sections)	Evidence level	Study overview	Key outcomes / conclusions
Muganza A, et al. <i>Global Journal of Human-Social Science</i> . 2014; 14(6): 1–12. ¹¹ 	Level 1	<ul style="list-style-type: none"> • RCT • Partial thickness burns (with paediatric subgroup) • ACTICOAT[◇] Dressing with BIOBRANE[◇] Dressing and MELOLIN versus SSD • ACTICOAT Dressing with BIOBRANE Dressing, n=49 (paediatrics n=26) • Standard dressing, n=47 (paediatrics n=19) 	Cost to treat was Rand 83,123 for ACTICOAT Dressing group patients and Rand 67,528 for standard dressing patients. Cost per healed burn was Rand 101,826 and 85,780, respectively.
Silver GM, et al. <i>J Burn Care Res</i> . 2007; 28(5): 715–719. ¹³ 	Level 1	<ul style="list-style-type: none"> • RCT • 20 burns requiring meshed autografts • Mean TBSA 17.9% • ACTICOAT Dressing and Sulfamylon[®]-soaked EXU-DRY Dressing 	A significant reduction in cost of dressings (p=0.024), costs of ancillary products (p=0.072), labour costs (p=0.01) and average total treatment costs (\$2,343 for ACTICOAT Dressing vs \$3,866 for Sulfamylon [®] -soaked EXU-DRY Dressing; p=0.043).
Wood F, et al. <i>Burns</i> . 2012; 38(6): 830–839. ¹⁷ 	Level 1	<ul style="list-style-type: none"> • RCT • Paediatric scalds • ACTICOAT Dressing with INTRASITE[◇] Dressing and DuoDERM[™] (standard treatment; n=4) versus BIOBRANE Dressing (n=4) and BIOBRANE Dressing with autologous cell suspension (n=5) • Median total TBSA of 4% 	Mean overall cost (Australian dollars) was \$9,431 for ACTICOAT Dressing + INTRASITE Dressing + DuoDERM [™] , \$22,733 for BIOBRANE Dressing and \$11,337 for BIOBRANE Dressing + autologous cell suspension.






Author (icons link to other sections)	Evidence level	Study overview	Key outcomes / conclusions
Argirova M, et al. Book chapter: <i>Skin Grafts-Indications, Applications and Current Research</i> . 2011: 237–264. ¹⁸  	Level 2	<ul style="list-style-type: none"> • Prospective cohort • Paediatric burns (78 superficial burns, 19 deep burns, 5 excised burns, 5 autografts, 5 donor sites) • Mean TBSA of 7.89% • ACTICOAT[◊] Dressing/ACTICOAT[◊] FLEX 3 Dressing/ACTICOAT[◊] FLEX 7 Dressing (n=68) versus SSD (n=43) 	<p>Treatment of a second degree (IIAB) burn wound (2,000 cm² area) with SSD was approximately 65% more expensive (€839) than with ACTICOAT Dressing.</p>
Cuttle L, et al. <i>Burns</i> . 2007; 33: 701–707. ²¹ 	Level 3	<ul style="list-style-type: none"> • Cohort study • Partial- or full-thickness burns (<20% TBSA) • ACTICOAT Dressing versus Silvazine[™] • 328 paediatric patients treated with Silvazine[™] between January 2000 and June 2001 compared with 241 patients treated with ACTICOAT Dressing between July 2002 and July 2003 	<p>Cost of treatment in terms of nursing time was reduced and pain medication decreased with ACTICOAT Dressing versus Silvazine[™]. Expenditure on pressure garments reduced to \$164,000 when the treatment regime had changed to ACTICOAT Dressing in contrast with \$210,000 for Silvazine[™] (Australian dollars). Number of inpatient bed days in comparison to Silvazine[™] decreased with ACTICOAT Dressing, even though the total number of new patients increased.</p>
Fong J, et al. <i>Burns</i> . 2005; 31 (5): 562–567. ²²  	Level 3	<ul style="list-style-type: none"> • Cohort study • All burns patients (superficial to deep partial thickness) • Mean TBSA 9.0–9.5% • Audit comparing ACTICOAT Dressing (19 patients) with Silvazine[™] (51 patients) 	<p>In treatment costs analysis (Australian dollars), 4 ACTICOAT Dressing patients were matched with 4 Silvazine[™] patients and showed a \$30,450 saving (4 ACTICOAT Dressing patients \$78,907; 4 Silvazine[™] patients \$109,357). The average saving per patient for ACTICOAT Dressing (excluding antibiotics, staffing and surgery) was \$7,613. The average dressing cost per patient for the ACTICOAT Dressing group was also lower compared with Silvazine[™] (\$946 vs \$1,533).</p>





Author (icons link to other sections)	Evidence level	Study overview	Key outcomes / conclusions
Glik J, et al. <i>Int Wound J.</i> 2018; 15(3): 344–349. ³  	Level 3	<ul style="list-style-type: none"> Retrospective case series Burns Implementation of a new management strategy in 2015 Silver dressings (ACTICOAT[◊] Dressing / ACTICOAT[◊] FLEX 3 Dressing) and antiseptics versus antibiotics and antimycotics n=2,000 	Total costs of antimicrobial prevention and treatment decreased by \$71,501 (USD). Expenditure decreased by \$106,055 (USD) for antibiotics and antimycotics, and increased by \$34,554 (USD) for dressings and antiseptics.
Harris J. <i>Am J Infect Control.</i> 2012; 40(5): e195–e196. Presentation 125. ⁵¹  	Level 3	<ul style="list-style-type: none"> Retrospective cohort Caesarean section ACTICOAT[◊] FLEX 7 Dressing (with PICO sNPWT in high-risk patients during 2012) introduced in 2011 as part of an infection prevention program versus prior standard care 	92 C-section SSIs were potentially avoided after intervention, yielding approximate cost savings of US dollars \$5,000,000.
Hickson E, et al. <i>Surg Infect.</i> 2015; 16: 174–177. ⁵²  	Level 3	<ul style="list-style-type: none"> Retrospective analysis Chart review of 4,942 caesarean deliveries from 2007 to 2012 Incremental interventions for low- and high-risk patients Post-operative ACTICOAT Dressing and incisional NPWT 	92 C-section SSIs were potentially avoided after intervention, yielding approximate cost savings of US dollars \$5,000,000.
Strand O, et al. <i>Ann Burns Fire Disasters.</i> 2010; 23(4): 182–185. ²³ 	Level 3	<ul style="list-style-type: none"> Retrospective case review Paediatric burns patients (mostly scalding water and flames) Mean TBSA % was 5.74 to 5.97% Before (2001) and after (2004 and 2007) implementation of a new care protocol ACTICOAT Dressing, INTRASITE[◊] GEL Dressing and ALLEVYN[◊] ADHESIVE Dressing In 2001, 292 paediatric burn patients (48 in-patients); in 2004, 371 patients (69 in-patients); in 2007, 397 patients (57 in-patients) 	Hospitalisation costs per in-patient were approximately Swedish kronor (kr) 67,725 in 2001 and kr 30,305 in 2004 and kr 24,440 in 2007, representing a saving of 55% and 64% versus 2001 costs.



Author (icons link to other sections)	Evidence level	Study overview	Key outcomes / conclusions
<p>Pearce FB, et al. <i>Wound Medicine</i>. 2014; 7: 18–23.⁴⁰</p>  	Level 4	<ul style="list-style-type: none"> • Retrospective comparative cost analysis • Bilateral axillary hidradenitis skin excision with split thickness skin grafting (n=7) • After excision ACTICOAT[◇] Dressing was applied with NPWT, followed by NPWT alone • After grafting N-Terface[®] and ACTICOAT Dressing were used as overlay 	<p>Mean hospital and provider charges were \$35,178 and \$10,826, respectively (n=4).</p>
<p>Cox SG, et al. <i>S Afr Med J</i>. 2011; 101(10): 728–731.⁷⁵</p>	Level 5	<ul style="list-style-type: none"> • Retrospective case series cost analysis • Paediatric burn patients • ACTICOAT Dressing versus standard dressings • n=4 	<p>Mean cost of mupirocin/chlorhexidine on JELONET was 1.6 times the cost of using ACTICOAT Dressing alone (Rand 129,700 vs Rand 83,316); mean cost saving per patient was Rand 46,383. Mean cost of using SSD 1% cream on a JELONET carrier was 1.3 times more than ACTICOAT Dressing (Rand 110,341 vs Rand 83,316); mean cost saving per patient was Rand 27,024. Mean cost of using povidone iodine 5% cream on a JELONET carrier was 1.3 times that of using ACTICOAT Dressing (Rand 108,999 vs Rand 83,316); mean cost saving per patient was Rand 25,683.</p>
<p>Cheng E, et al. Poster: <i>Australian and New Zealand Burn Association Annual Scientific Meeting</i>. 2004.³²</p> 	Other	<ul style="list-style-type: none"> • Cost effectiveness analysis (cost assumptions based on a 10-year-old boy of 35kg and 137cm) • 447 paediatric patients • Mean TBSA was 2.5 to 3.0% • ACTICOAT Dressing (n=241) versus Silvazine[™] (n=206) 	<p>Estimated cost savings of 22–29% for smaller burns (1–5% TBSA) and 16–18% for larger burns (15–25% TBSA) with ACTICOAT Dressing compared with Silvazine[™].</p>

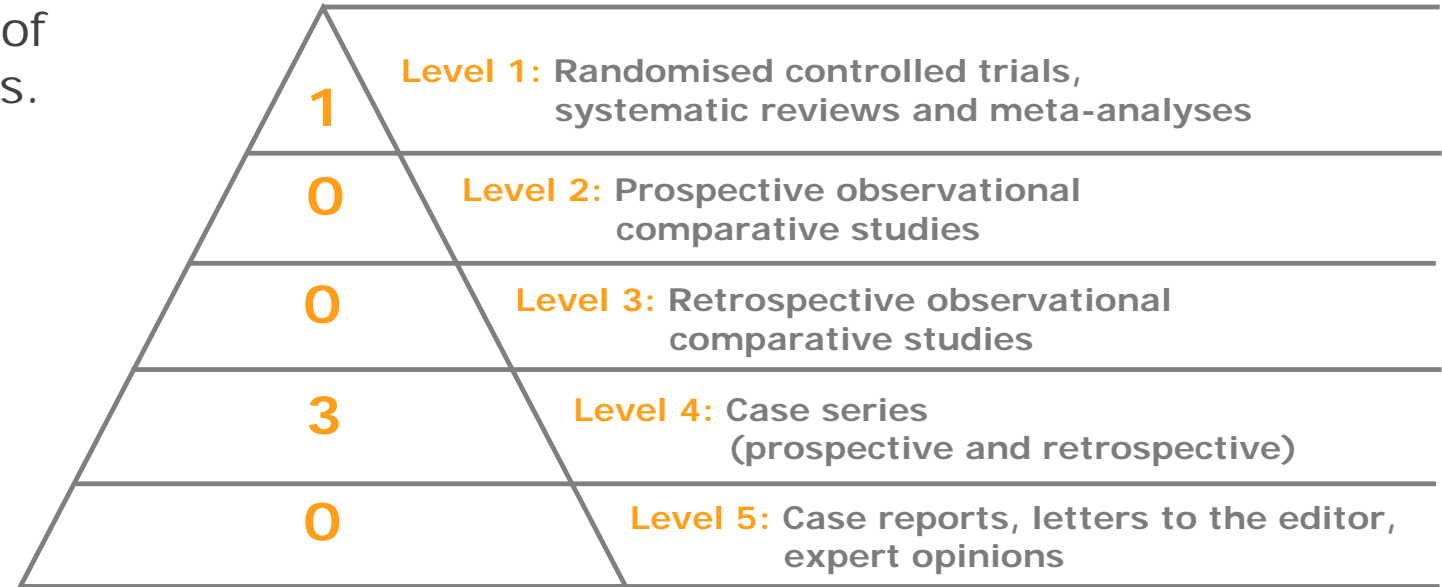


Author (icons link to other sections)	Evidence level	Study overview	Key outcomes / conclusions
Gee Kee E, et al. <i>Burns</i> . 2017; 43(4): 724–732. ⁷⁶	Other	<ul style="list-style-type: none"> • Cost analysis • Paediatric partial thickness burns ≤10% TBSA • ACTICOAT[◊] Dressing (n=31), ACTICOAT Dressing with Mepitel[™] (n=32) and Mepilex[™] Ag (n=33) 	Costs (dressing, labour, analgesics, scar management) were considerably lower in the Mepilex [™] Ag group (median AUD \$94.45) compared to ACTICOAT Dressing (median \$244.90) and ACTICOAT Dressing with Mepitel [™] (median \$196.66) interventions.
Leaper D, et al. <i>J Med Econ</i> . 2010; 13(3): 447–452. ⁷⁷	Other	<ul style="list-style-type: none"> • Cost analysis • Almost 240,000 surgeries in England from Oct 1997 to Sep 2005, resulted in 7,194 hospital-detected SSIs • Economic model based on an SSI incidence of 3% (range: 1% for knee prosthesis to 13.1% for amputation) • ACTICOAT Dressing versus OPSITE[◊] POST-OP Dressing 	At a baseline risk of 10%, an antimicrobial barrier dressing strategy is cost neutral, as long as the incidence of infection is reduced by ≥9%. Switching from a film dressing to an antimicrobial barrier dressing in medium- to high-risk patients reduces the incidence of infection by 9 cases per 1,000 operations and infection-attributable bed-days by 99 days per 1,000 (saving £28,710 at £290 per day). At 35% efficacy, expenditure on dressings would be higher by £30,760 per 1,000 patients, and the cost of treating infection would be lower by £111,650, resulting in a net cost saving of £80,890.
Malic C, et al. <i>Plast Surg</i> . 2014; 22(2): 99–102. ³³ 	Other	<ul style="list-style-type: none"> • Cost analysis of six studies • Paediatric scald burns • Mean TBSA was 6.3–6.8% • ACTICOAT Dressing (n=709) versus SSD (n=538) 	Estimated mean total cost of care per patient (Canadian dollars) was \$17,220 for ACTICOAT Dressing and \$61,140 for SSD.
Nherera L, et al. <i>Wounds</i> . 2018; 30(6): 160–167. ⁴ 	Other	<ul style="list-style-type: none"> • Cost effectiveness analysis • Partial-thickness burns (1,873 patients) • Mean TBSA <20% • ACTICOAT Dressing versus Aquacel[™] Ag versus Mepilex[™] Ag versus SSD • US payer perspective 	Estimated QALYs were 0.970, 0.969 and 0.969, and mean cost per patient was \$15,892, \$23,799, and \$24,269 for ACTICOAT Dressing, Aquacel [™] Ag, and Mepilex [™] Ag dressings, respectively. Cost per patient for SSD was \$31,538 and estimated QALYs were 0.919.

This section summarises key studies supporting the **safety and tolerability** of using ACTICOAT[◇] Antimicrobial Dressings.

Studies that are included elsewhere in the evidence compendium can be identified by navigation icons, which link to the relevant sections.

Evidence pyramid








Information correct up to: 30 March 2020



Safety and tolerability



Author (icons link to other sections)	Evidence level	Study overview	Key outcomes / conclusions
Huang Y, et al. <i>Burns</i> . 2007; 33(2): 161–166. ⁸  	Level 1	<ul style="list-style-type: none"> • RCT • 166 wounds (98 patients) • Mean burn size 54.2% TBSA • ACTICOAT[◊] Dressing and SSD 	<p>No significant difference between ACTICOAT Dressing and SSD in routine blood tests, liver and renal function tests. No relevant side effects reported with ACTICOAT Dressing.</p>
Moiemen NS, et al. <i>Burns</i> . 2011; 37(1): 27–35. ²⁷ 	Level 4	<ul style="list-style-type: none"> • Cohort study • 6 patients with burns >20% TBSA (grafted and non-grafted areas and donor sites) • Evaluated serum silver levels, biochemistry and haematology before, during and after application of ACTICOAT Dressings 	<p>No adverse events due to haematological or biochemical abnormalities. Serum silver levels were elevated but remained similar to that reported following the use of SSD. The authors concluded that ACTICOAT Dressing is safe to use on patients with burns, even when they are extensive.</p>
Sibbald RG, et al. <i>Adv Skin Wound Care</i> . 2007; 20(10): 549–558. ⁴² 	Level 4	<ul style="list-style-type: none"> • Case-controlled study • 15 patients with VLUs • ACTICOAT[◊] 7 Dressing under compression • Serum samples were obtained at baseline, 4, 8 and final assessment (12 weeks or at time of wound healing) <ul style="list-style-type: none"> • 43 samples; 11 patients 	<p>No clinically relevant changes occurred in serum silver concentrations or haematology and biochemistry results. Median silver concentration was 0.3ng/ml at baseline (range, 0.2–1.9ng/mL) and 0.7ng/mL at final assessment (range, 0.2–3.1ng/ml). All blood silver levels remained within the normal range (0–14.9ng/ml) for all patients throughout the study.</p>
Vlachou E, et al. <i>Burns</i> . 2007; 33(8): 979–985. ³¹ 	Level 4	<ul style="list-style-type: none"> • Cohort / case-controlled study • 30 patients with deep partial-thickness or full-thickness burns of ≥2% TBSA, requiring autografting • ACTICOAT Dressing and ACTICOAT 7 Dressing 	<p>The authors concluded that the use of ACTICOAT Dressing was not associated with clinical, biochemical or haematological signs of toxicity and was safe for treating people with burns.</p>

1. Woodmansey EJ, Roberts CD. Appropriate use of dressings containing nanocrystalline silver to support antimicrobial stewardship in wounds. *Int Wound J*. 2018;15(6):1025-1032.
2. Gago M, Garcia F, Gaztelu V, Verdu J, Lopez P, Nolasco A. A comparison of three silver-containing dressings in the treatment of infected, chronic wounds. *Wounds*. 2008;20(10):273-8.
3. Glik J, Łabuś W, Kitala D, et al. A 2000 patient retrospective assessment of a new strategy for burn wound management in view of infection prevention and treatment. *Int Wound J*. 2018;15(3):344-349.
4. Nherera L, Trueman P, Roberts C, Berg L. Cost-effectiveness analysis of silver delivery approaches in the management of partial-thickness burns. *Wounds*. 2018;30(6):160-167.
5. Nherera LM, Trueman P, Roberts CD, Berg L. A systematic review and meta-analysis of clinical outcomes associated with nanocrystalline silver use compared to alternative silver delivery systems in the management of superficial and deep partial thickness burns. *Burns*. 2017;43(5):939-948.
6. Gravante G, Caruso R, Sorge R, Nicoli F, Gentile P, Cervelli V. Nanocrystalline silver: a systematic review of randomized trials conducted on burned patients and an evidence-based assessment of potential advantages over older silver formulations. *Ann Plast Surg*. 2009;63(2):201-205.
7. Gee Kee EL, Kimble RM, Cuttle L, Khan A, Stockton KA. Randomized controlled trial of three burns dressings for partial thickness burns in children. *Burns*. 2015;41(5):946-955.
8. Huang Y, Li X, Liao Z, Zhang G, Liu Q, Tang J, Peng Y, Liu X, Luo Q. A randomized comparative trial between Acticoat and SD-Ag in the treatment of residual burn wounds, including safety analysis. *Burns*. 2007;33(2):161-166.
9. Hyland EJ, D'Cruz R, Menon S, et al. Biobrane™ versus acticoat™ for the treatment of mid-dermal pediatric burns: a prospective randomized controlled pilot study. *Int J Burns Trauma*. 2018;8(3):63-67.
10. Muangman P, Chuntrasakul C, Silthram S, et al. Comparison of efficacy of 1% silver sulfadiazine and Acticoat for treatment of partial-thickness burn wounds. *J Med Assoc Thai*. 2006;89(7):953-958.
11. Muganza A, Cullingworth L. A prospective single-centre randomised controlled study to compare the time to healing of partial thickness burn wounds treated with Versajet, Biobrane and Acticoat to conventional therapy. *Global Journal of Human-Social Science*. 2014;14(6):1-12.
12. Palombo M, Anniboletti T, Fasciani L, Delli Santi G, Schirosi M. Smart dressings for the reduction of burns infections. *Burns*. 2011;37:S8-S9.
13. Silver GM, Robertson SW, Halerz MM, Conrad P, Supple KG, Gamelli RL. A silver-coated antimicrobial barrier dressing used postoperatively on meshed autografts: a dressing comparison study. *J Burn Care Res*. 2007;28(5):715-9.
14. Tredget EE, Shankowsky HA, Groeneveld A, Burrell R. A matched-pair, randomized study evaluating the efficacy and safety of Acticoat silver-coated dressing for the treatment of burn wounds. *J Burn Care Rehabil*. 1998;19(6):531-537.
15. Varas RP, O'Keeffe T, Namias N, et al. A prospective, randomized trial of Acticoat versus silver sulfadiazine in the treatment of partial-thickness burns: which method is less painful? *J Burn Care Rehabil*. 2005;26(4):344-347.
16. Verbelen J, Hoeksema H, Heyneman A, Pirayesh A, Monstrey S. Aquacel® Ag dressing versus Acticoat dressing in partial thickness burns: a prospective, randomized, controlled study in 100 patients. Part 1: burn wound healing. *Burns*. 2014;40(3):416-427.
17. Wood F, Martin L, Lewis D, et al. A prospective randomised clinical pilot study to compare the effectiveness of Biobrane® synthetic wound dressing, with or without autologous cell suspension, to the local standard treatment regimen in paediatric scald injuries. *Burns*. 2012;38(6):830-839.
18. Argirova M, Hadjiiski O. Application of the nanocrystalline silver in treatment of burn wounds in children. Book chapter in: *Skin Grafts-Indications, Applications and Current Research*. 2011:237-264. Published: August 29th 2011. DOI: 10.5772/892.
19. Demling RH, Leslie DeSanti MD. The rate of re-epithelialization across meshed skin grafts is increased with exposure to silver. *Burns*. 2002;28(3):264-266.
20. Peters DA, Verchere C. Healing at home: Comparing cohorts of children with medium-sized burns treated as outpatients with in-hospital applied Acticoat to those children treated as inpatients with silver sulfadiazine. *J Burn Care Res*. 2006;27(2):198-201.
21. Cuttle L, Naidu S, Mill J, Hoskins W, Das K, Kimble RM. A retrospective cohort study of Acticoat versus Silvazine in a paediatric population. *Burns*. 2007;33(6):701-707.

References



22. Fong J, Wood F, Fowler B. A silver coated dressing reduces the incidence of early burn wound cellulitis and associated costs of inpatient treatment: comparative patient care audits. *Burns*. 2005;31(5):562-567.
23. Strand O, San Miguel L, Rowan S, Sahlqvist A. Retrospective comparison of two years in a paediatric burns unit, with and without acticoat as a standard dressing. *Ann Burns Fire Disasters*. 2010;23(4):182-185.
24. Tonkin C, Wood F. Nanocrystalline silver reduces the need for antibiotic therapy in burn wounds. *Primary Intention*. 2005;13(4):163–168.
25. Andreone A, Den Hollander D. A retrospective study on the use of dermis micrografts in platelet-rich fibrin for the resurfacing of massive and chronic full-thickness burns. *Stem Cells International*. 2019:1-9. Article ID 8636079.
26. Jain A, Husain J, Singh A. Evaluation of nano-crystalline silver dressings in superficial partial thickness burns. *JCDR*. 2019;13(11):PC05-PC08.
27. Moiemmen NS, Shale E, Drysdale KJ, Smith G, Wilson YT, Papini R. Acticoat dressings and major burns: systemic silver absorption. *Burns*. 2011;37(1):27-35.
28. Lonie S, Baker P, Teixeira RP. Healing time and incidence of hypertrophic scarring in paediatric scalds. *Burns*. 2017;43(3):509-513.
29. Rustogi R, Mill J, Fraser JF, Kimble RM. The use of Acticoat in neonatal burns. *Burns*. 2005;31(7):878-882.
30. Selvarajah D, Bollu BK, Harvey J, et al. Acticoat versus biobrane: a retrospective review on the treatment of paediatric mid-dermal torso burns. *Int J Burns Trauma*. 2019;9(4):82-87.
31. Vlachou E, Chipp E, Shale E, Wilson YT, Papini R, Moiemmen NS. The safety of nanocrystalline silver dressings on burns: a study of systemic silver absorption. *Burns*. 2007;33(8):979-85.
32. Cheng E, Fraser J, Mill J, Kimble R. A tale of two dressings part 4: Money matters. Poster presented at the Australian and New Zealand Burn Association Annual Scientific Meeting; 5-7 November 2004, Brisbane, Australia.
33. Malic C, Verchere C, Arneja JS. Inpatient silver sulphadiazine versus outpatient nanocrystalline silver models of care for pediatric scald burns: A value analysis. *Plast Surg*. 2014;22(2):99-102.
34. Miller CN, Newall N, Kapp SE, Lewin G, Karimi L, Carville K, Gliddon T, Santamaria NM. A randomized-controlled trial comparing cadexomer iodine and nanocrystalline silver on the healing of leg ulcers. *Wound Repair Regen*. 2010;18(4):359-367.
35. Miller CN, Carville K, Newall N, et al. Assessing bacterial burden in wounds: comparing clinical observation and wound swabs. *Int Wound J*. 2011;8(1):45-55.
36. Pajardi G, Rapisarda V, Somalvico F, et al. Skin substitutes based on allogenic fibroblasts or keratinocytes for chronic wounds not responding to conventional therapy: a retrospective observational study. *Int Wound J*. 2016;13(1):44-52.
37. Forner-Cordero I, Navarro-Monsoliu R, Muñoz-Langa J, Alcober-Fuster P, Rel-Monzó P. Use of a nanocrystalline silver dressing on lymphatic ulcers in patients with chronic lymphoedema. *J Wound Care*. 2007;16(5):235-239.
38. Giovannini UM. The use of V.A.C. in combination with ACTICOAT™ 7 – a clinical evaluation. Presentation at the 2nd World Union of Wound Healing Societies, 8-13 July, 2004; Paris, France. *Wound Repair Regen*. 2005;13(3):A49-87.
39. Ivins N, Bamford A, Palmer S, Dharma H. A prospective, non-comparative, clinical in-market assessment of the performance of non-adhesive highly conformable antimicrobial silver barrier* (HCASB) dressing. Poster presented at the 27th Annual Clinical Symposium on Advances in Skin and Wound Care. 20-23 October 2012, Las Vegas, NV, USA.
40. Pearce FB, Richardson KA. Cost comparison of split thickness skin grafting with and without bilayer dermal regenerative templates for bilateral axillary hidradenitis suppurativa: A retrospective comparison study. *Wound Medicine*. 2014;7:18-23.
41. Sibbald RG, Browne AC, Coutts P, Queen D. Screening evaluation of an ionized nanocrystalline silver dressing in chronic wound care. *Ostomy Wound Management*. 2001;47(10):38-43.
42. Sibbald RG, Contreras-Ruiz J, Coutts P, Fierheller M, Rothman A, Woo K. Bacteriology, inflammation, and healing: a study of nanocrystalline silver dressings in chronic venous leg ulcers. *Adv Skin Wound Care*. 2007;20(10):549-558.

43. Strohal R, Schelling M, Takacs M, Jurecka W, Gruber U, Offner F. Nanocrystalline silver dressings as an efficient anti-MRSA barrier: a new solution to an increasing problem. *J Hosp Infect.* 2005;60(3):226-230.
44. Angirasa AK, Willrich A, Cooper B, Stuck R. Combining bioengineered human dermal replacement and multilayered compression dressings to manage ulcers in a person with diabetes mellitus: a case study. *Ostomy Wound Manage.* 2006;52(5):60-64.
45. Arhi C, El-Gaddal A. Use of a silver dressing for management of an open abdominal wound complicated by an enterocutaneous fistula-from hospital to community. *J Wound Ostomy Continence Nurs.* 2013;40(1):101-103.
46. Harish V, Maitz PK. Uninterrupted continuous negative pressure wound therapy is safe and can facilitate engraftment of dermal regeneration templates. *J Plast Reconstr Aesthet Surg.* 2014;67(7):1011-1013.
47. Richards AJ, Hagelstein SM, Patel GK, Ivins NM, Sweetland HM, Harding KG. Early use of negative pressure therapy in combination with silver dressings in a difficult breast abscess. *Int Wound J.* 2011;8(6):608-611.
48. Wong S, Brahim Z, Aminuddin NA, Nasirudin N. Management of malodour fungating wound with nanocrystalline silver coated dressing. *Med J Malaysia.* 2017;72:316-317.
49. Doshi J, Karagama Y, Buckley D, Johnson I. Observational study of bone-anchored hearing aid infection rates using different post-operative dressings. *J Laryngol Otol.* 2006;120(10):842-844.
50. Narayan P, Brown M, Gould J. Use of silver-impregnated dressings to reduce neurosurgical infections. *Child's Nervous System.* 2014;30(11):1953 (Abstract FP43).
51. Harris J. Using a multi-faceted active change process and infection prevention to reduce post-op C-section infections. *Am J Infect Control.* 2012;40(5):e195–e196. Presentation 125.
52. Hickson E, Harris J, Brett D. A journey to zero: reduction of post-operative cesarean surgical site infections over a five-year period. *Surg Infect.* 2015;16(2):174-177.
53. Carnali M, Ronchi R, Finocchi L, Spuri Capesciotti S, Paggi B. Retrospective study on the use of negative pressure wound therapy in the treatment of pilonidal cysts (sinus pilonidalis) operated on using an open technique or complicated by dehiscence of the surgery site through sepsis. *Acta Vulnologica.* 2016;14(1):24-39.
54. Choi WW, McBride CA, Kimble RM. Negative pressure wound therapy in the management of neonates with complex gastroschisis. *Pediatr Surg Int.* 2011;27(8):907-911.
55. Dunn RM, Ignatz R, Mole T, Cockwill J, Smith JM. Assessment of gauze-based negative pressure wound therapy in the split-thickness skin graft clinical pathway-an observational study. *Eplasty.* 2011;11:e14.
56. Keen JS, Desai PP, Smith CS, Suk M. Efficacy of hydrosurgical debridement and nanocrystalline silver dressings for infection prevention in type II and III open injuries. *Int Wound J.* 2012;9(1):7-13.
57. Kępa K, Krzych Ł, Waclawczyk T, Krejca M. The use of negative pressure wound therapy in the treatment of wound infections – a single-center 12-month experience. *Polish Journal of Thoracic and Cardiovascular Surgery.* 2013;10(3):204-210.
58. Bhattacharyya M, Bradley H. Management of a difficult-to-heal chronic wound infected with methycillin-resistant staphylococcus aureus in a patient with psoriasis following a complex knee surgery. *Int J Low Extrem Wounds.* 2006;5(2):105-108.
59. Bhattacharyya M, Bradley H. A case report of the use of nanocrystalline silver dressing in the management of acute surgical site wound infected with MRSA to prevent cutaneous necrosis following revision surgery. *Int J Low Extrem Wounds.* 2008;7(1):45-48.
60. Kimble R, Cheng E, Smith J, Cleghorn G. Successful use of Acticoat™ Dressing in the treatment of a child with pyoderma. Book Chapter. Published 2015. 10.13134/RG.2.1.4363.9200.
61. Riordan NH, George BA, Chandler TB, McKenna RW. Case report of non-healing surgical wound treated with dehydrated human amniotic membrane. *J Transl Med.* 2015;13:242.
62. Sakata S, Das Gupta R, Leditschke JF, Kimble RM. Extensive necrotising fasciitis in a 4-day-old neonate: a successful outcome from modern dressings, intensive care and early surgical intervention. *Pediatr Surg Int.* 2009;25(1):117-119.
63. Sharp E. Single-use NPWT for the treatment of complex orthopaedic surgical and trauma wounds. *J Wound Care.* 2013;22(10 Suppl):S5-9.

64. Zhou K, Krug K, Brogan MS. Management of a dehisced hand wound using hydrogen peroxide, electrical stimulation, silver-containing dressings, and compression: a case study. *Ostomy Wound Manage*. 2015;61(7):32-37.
65. Wright JB, Lam K, Olson ME, Burrell RE. Is antimicrobial efficacy sufficient? A question concerning the benefits of new dressings. *Wounds*. 2003;15(5):132-144.
66. Newton H. Reducing MRSA bacteraemias associated with wounds. *Wounds UK*. 2010;6:56-65.
67. Pour SM. Use of negative pressure wound therapy with silver base dressing for necrotizing fasciitis. *J Wound Ostomy Continence Nurs*. 2011;38(4):449-452.
68. Hurd T, Rossington A, Trueman P, Smith J. A retrospective comparison of the performance of two negative pressure wound therapy systems in the management of wounds of mixed etiology. *Adv Wound Care*. 2017;6(1):33-37.
69. Goldstein JA, Iorio ML, Brown B, Attinger CE. The use of negative pressure wound therapy for random local flaps at the ankle region. *J Foot Ankle Surg*. 2010;49(6):513-516.
70. Belek KA, Alkureishi LW, Dunn AA, Devcic Z, Kuri M, Lee CK, Hansen SL. Single-stage reconstruction of a devastating antebrachial injury with brachial artery, median nerve, and soft tissue deficit: a case report and review of the literature. *Eplasty*. 2010;10:e33.
71. Chariker M, Ford R, Rasmussen E, Schotter E. CASE REPORT Management of Periauricular and Auricular Necrotizing Wound From Brown Recluse Spider Bite Using Negative Pressure Wound Therapy and Wound Interface Modulation. *Eplasty*. 2012;12:e26.
72. Forlee M. International Case Studies. Retrospective chronic and post-surgical wound case series: Understanding RENASYS™ TOUCH. *Wounds International*. January 2020. Available at: https://www.woundsinternational.com/resources/all/0/date/desc/cont_type/46. Accessed 21 April 2020.
73. González Alaña I, Torrero López JV, Martín Playá P, Gabilondo Zubizarreta FJ. Combined use of negative pressure wound therapy and Integra® to treat complex defects in lower extremities after burns. *Ann Burns Fire Disasters*. 2013;26(2):90-93.
74. Psoinos CM, Igotz RA, Lalikos JF, Fudem G, Savoie P, Dunn RM. Use of gauze-based negative pressure wound therapy in a pediatric burn patient. *J Pediatr Surg*. 2009;44(12):e23-26.
75. Cox SG, Cullingworth L, Rode H. Treatment of paediatric burns with a nanocrystalline silver dressing compared with standard wound care in a burns unit: a cost analysis. *S Afr Med J*. 2011;101(10):728-31.
76. Gee Kee E, Stockton K, Kimble RM, Cuttle L, Mcphail SM. Cost-effectiveness of silver dressings for paediatric partial thickness burns: An economic evaluation from a randomized controlled trial. *Burns*. 2017;43(4):724-732.
77. Leaper D, Nazir J, Roberts C, Searle R. Economic and clinical contributions of an antimicrobial barrier dressing: a strategy for the reduction of surgical site infections. *J Med Econ*. 2010;13(3):447-452.

Advanced Wound Management
Smith+Nephew Medical Ltd
101 Hessle Road
Hull HU3 2BN, UK
T +44 (0) 1482 225181
F +44 (0) 1482 328326
www.smith-nephew.com

◇Trademark of Smith+Nephew
All Trademarks acknowledged
©May 2020 Smith+Nephew
AWM-AWC-25217

For further information about
ACTICOAT◇ Antimicrobial Dressings please contact:
Tom Newton, Senior Global Marketing Manager
Email: Tom.Newton@smith-nephew.com
Tel: +44 (0)7583 073045

For detailed product information, including indications for use,
contraindications, precautions and warnings, please consult the
product's applicable Instructions for Use (IFU) prior to use.

Smith+Nephew