

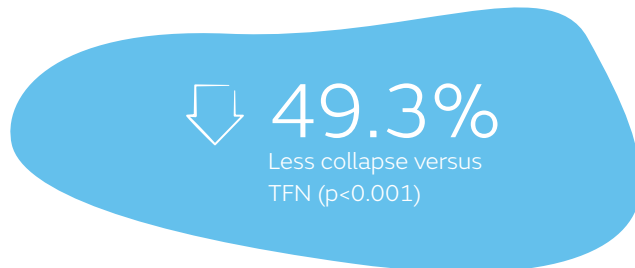
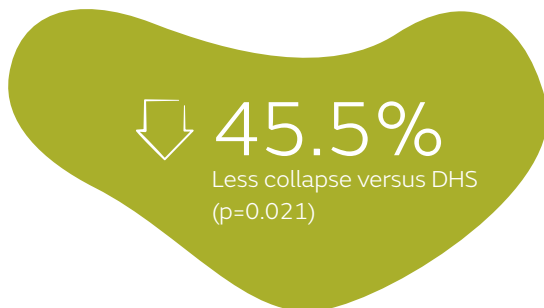
+ Evidence in focus

Publication summary: Ricci MJ, et al., *J Orthop Trauma* (2019)*

Smith+Nephew

Significantly less collapse with TRIGEN[◇] INTERTAN[◇] Intertrochanteric Antegrade Nail compared to dynamic hip screw (DHS) and trochanteric fixation nail (TFN) for intertrochanteric femur fractures

+ Plus points



Overview

Retrospective, single-centre cohort study comparing secondary displacement (collapse) of two-part intertrochanteric femur fractures fixated with:

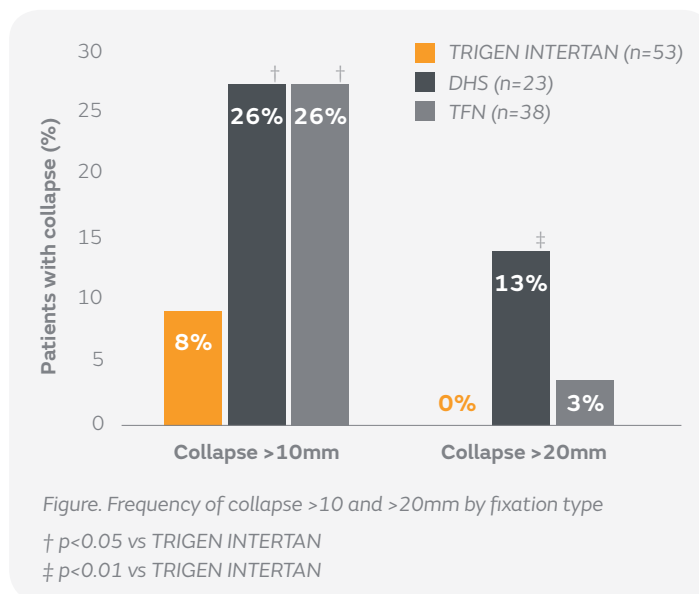
- TRIGEN INTERTAN (n=53)

- DHS (n=23; DePuy Synthes, Paoli, PA)
- TFN (n=38; DePuy Synthes, Paoli, PA)

Collapse was measured by comparing radiographs at final follow-up (mean, 7.8 months) with immediate postoperative images

Results

- TRIGEN INTERTAN demonstrated significantly less collapse compared to DHS (mean: 3.7 vs 6.8mm, p=0.021), and TFN (mean: 3.7 vs 7.3mm, p<0.001)
- Significantly fewer patients treated with TRIGEN INTERTAN had collapse >10mm, compared to DHS and TFN (p<0.028 and p<0.014, respectively; Figure)
- Significantly fewer patients treated with TRIGEN INTERTAN had collapse >20mm compared to DHS (p<0.007; Figure)
- No collapse >20mm occurred in patients treated with TRIGEN INTERTAN
- 3% of TFN-treated patients had collapse >20mm, however, there was no significant difference between TFN and TRIGEN INTERTAN groups



Conclusions

Stability of two-part intertrochanteric fractures was improved when fixated with TRIGEN INTERTAN compared to DHS and TFN. The authors suggested that the reduced stability of single screw devices may be due to their lack of rotational control.

Citation

*Ricci MJ, McAndrew CM, Miller AN, Kamath G, Ricci WM. Are two-part intertrochanteric femur fractures stable and does stability depend on fixation method? *J Orthop Trauma*. 2019;33(9):428-431. Available at: [Journal of Orthopaedic Trauma](https://doi.org/10.1097/BOT.0000000000000688)