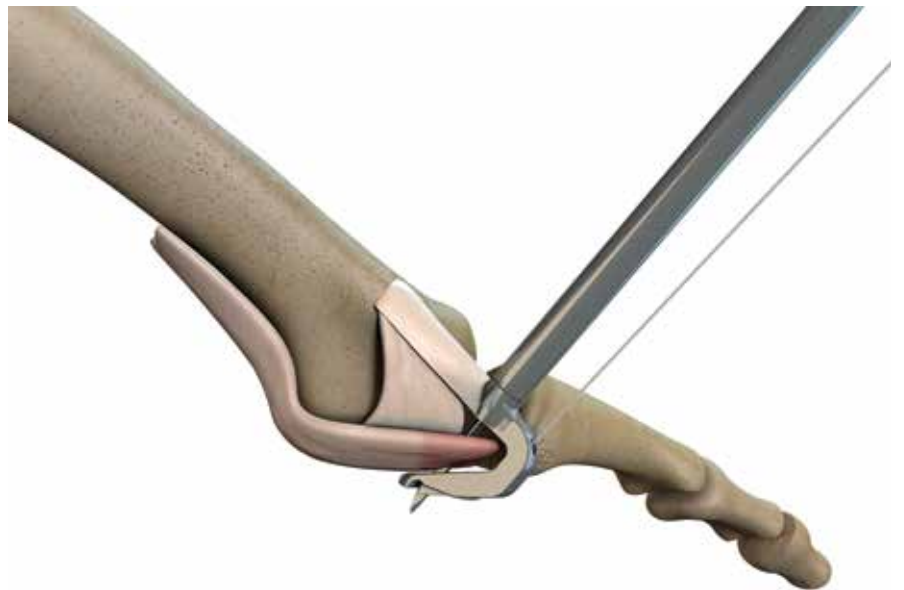


Foot and Ankle Technique Guide  
**Metatarsophalangeal (MTP) Bilateral Joint Repair**



Prepared in consultation with:  
**Phinit Phisitkul, MD**  
Department of Orthopedics and Rehabilitation  
University of Iowa  
Iowa City, IA

# HAT-TRICK<sup>◇</sup> Lesser Toe Repair System

## MTP Bilateral Joint Repair Surgical Technique

The following technique guide contains a summary of medical techniques and opinions based upon the training and expertise of the surgeon advisory team, along with its knowledge of the Smith & Nephew HAT-TRICK Lesser Toe Repair System. Smith & Nephew does not provide medical advice and recommends that surgeons exercise their own professional judgment when determining a patient's course of treatment. This guide is presented for educational purposes only.

### **HAT-TRICK Orthopaedic Advisory Team**

Ned Amendola, MD  
Florian Nickisch, MD  
Phinit Phisitkul, MD  
Charles Saltzman, MD

### **HAT-TRICK Podiatric Advisory Team**

Emily Cook, DPM  
Jeremy Cook, DPM  
David Edwards, DPM  
Mickey Stapp, DPM

## Table of contents

<b>Introduction</b> .....	3
<b>Position the patient</b> .....	4
<b>MTP Bilateral Joint Repair Technique</b> .....	4
Expose the joint and prepare for the repair .....	4
Place the sutures in the plantar plate and collateral ligaments.....	6
Drill the bone tunnel using the Phalangeal Drill Guide .....	11
Tension the construct and complete the repair .....	16
Postoperative care.....	18
Notes on Plantar Plate Access .....	19
<b>Ordering information</b> .....	20

# Introduction

The HAT-TRICK<sup>®</sup> Lesser Toe Repair System is a three-part solution to lesser toe injuries:

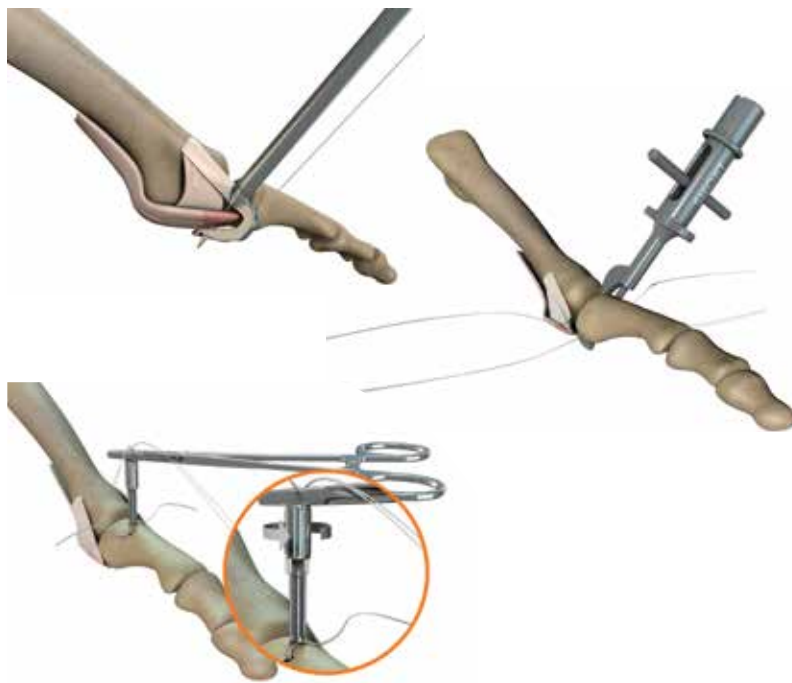
- The HAT-TRICK MTP Joint Repair System (Unilateral and Bilateral)
- The HAT-TRICK Osteotomy Guide for metatarsal shortening procedures
- The HAT-TRICK PIP Fusion System

This technique guide provides a description of the procedures for the HAT-TRICK MTP Bilateral Joint Repair System. For information about additional lesser toe repair solutions using the HAT-TRICK Lesser Toe Repair System, please refer to those specific technique guides.

## HAT-TRICK MTP Bilateral Joint Repair System

Flexor tendon transfers and Weil osteotomies often lead to loss of ROM, stiffness, and residual pain.<sup>1,2,3,4</sup> The HAT-TRICK MTP Bilateral Joint Repair System provides a complete repair of the lesser MTP joint that is less invasive and more anatomic than standard of care techniques. Benefits of the HAT-TRICK System include:

- Anatomic reattachment of collateral ligaments
- Anatomic distal reattachment of the plantar plate
- Preservation of the biomechanical axis, which can be lost when performing a metatarsal osteotomy
- Elimination of the need to release the plantar plate from the metatarsus
- Controlled tensioning of collateral ligaments and plantar plate



The HAT-TRICK MTP Joint Repair System consists of individual single-use disposable procedure packs for both unilateral or bilateral ligament repair, and a sterilization tray with reusable instruments.

Information regarding the instruments used in each procedure can be found in the “Ordering Information” section at the end of this document.

# Position the patient

1. Place the patient in the supine position with a thigh tourniquet and the foot at the end of the bed.
2. Place a sterile bump underneath the knee of the operative leg so that the foot is in plantar flexion, almost parallel to the ground.

## MTP Bilateral Joint Repair Technique

*Prior to performing this technique, consult the Instructions for Use documentation provided with each device – including indications, contraindications, warnings, cautions and instructions.*

### Expose the joint and prepare for the repair

*In a case where two adjacent MTP joints are being repaired, the incision can be placed in the web space. The FDL can be preserved, z-lengthened, or completely transected depending on the degree of extension contracture of the MTP joint.*

1. Create a longitudinal curvilinear skin incision from the mid-metatarsal to the mid-proximal phalanx while protecting the digital nerve branches. Ensure that the Extensor Digitorum Longus (EDL) Tendon is not damaged during the procedure.
2. Release the extensor hood longitudinally on the side of collateral ligament attenuation to expose the metatarsophalangeal (MTP) joint capsule (Figure 1).

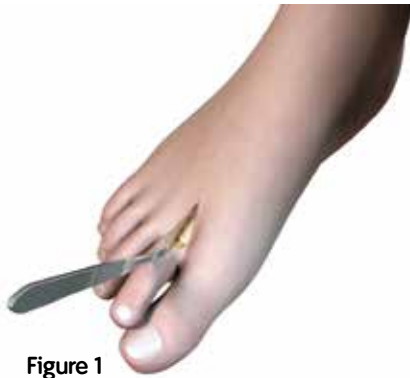

Figure 1

3. If necessary, retract the tissue to expose the site using the Trigger Retractor (REF 72204348) (Figure 2).

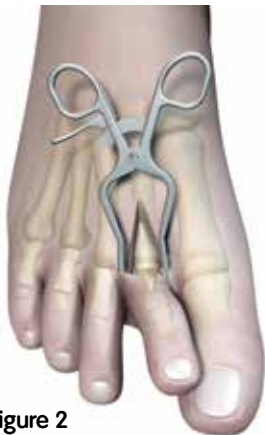

Figure 2

4. Distract the MTP joint using the Small Joint Pin Distractor (REF 72204347) and 1.6mm or 1.1mm K-wires on both sides at approximately 1cm from the joint (Figure 3).

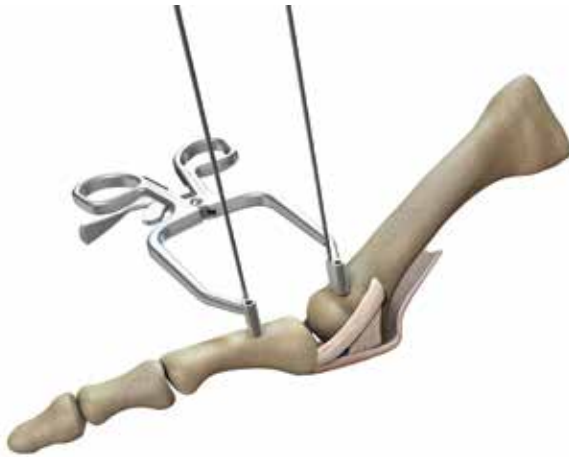

Figure 3

5. Under tension, dissect both collateral ligaments (Figure 4a) and the entire plantar plate (Figure 4b) using a #15 blade precisely at the level of the metatarsal head. Ensure that the Flexor Digitorum Longus Tendon (FDL) is not damaged during the dissection. Remove the residual parts of the collateral ligaments and the plantar plate on the base of the proximal phalanx with rongeurs and a curved blade.

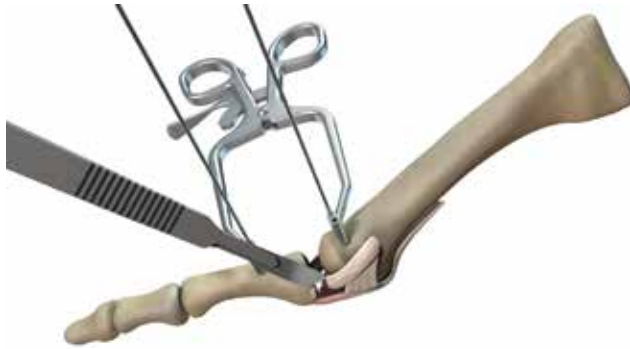

Figure 4a

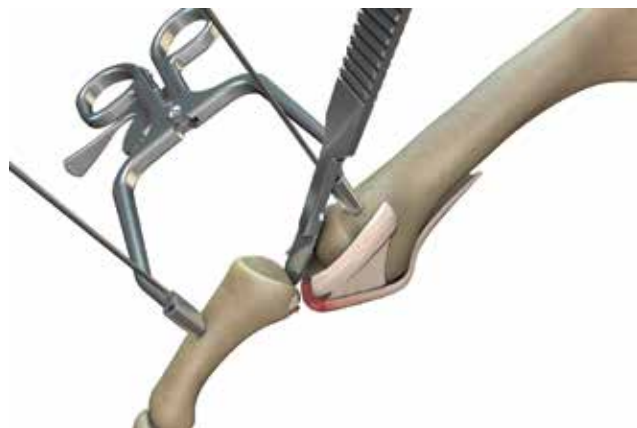


Figure 4b

6. Denude the ligament insertion sites using the Double Ended Rasp (REF 72204349) to promote healing (Figure 5).

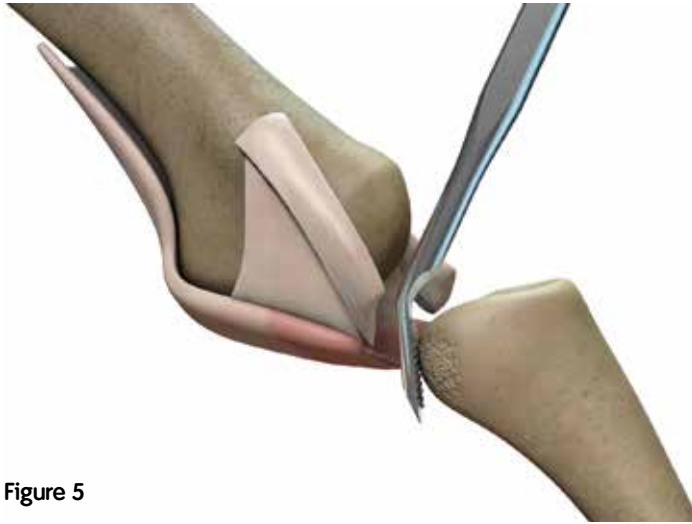


Figure 5

Place the sutures in the plantar plate and collateral ligaments

1. Use the probe side of the Cottle Elevator (REF 72204346) to identify the FDL tunnel just underneath the plantar plate.
2. Place the HAT-TRICK<sup>®</sup> DART Suture Passer Needle into the DART Suture Passer (REF 72204320) by depressing the button on the suture passer. Ensure that the bottom of the "I" mark on the needle aligns with the top of the suture passer.

Do not push the needle beyond the distal end of the "I" mark (Figure 6).

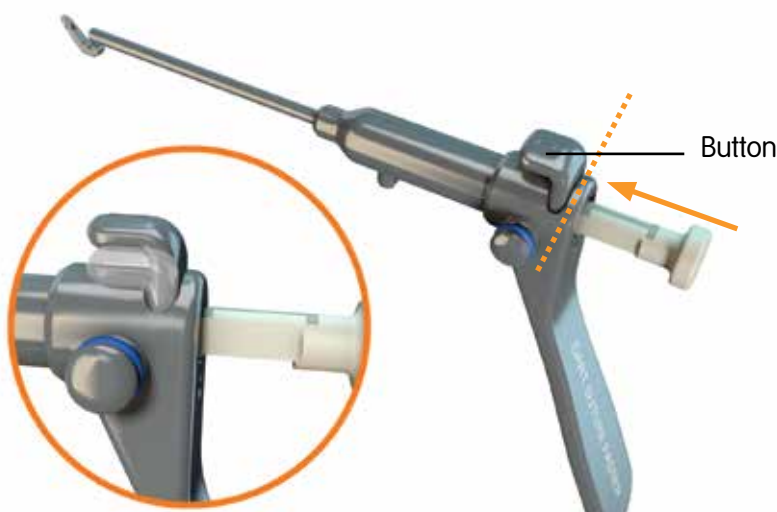


Figure 6

3. Load the 2-0 ULTRABRAID® Suture from the procedure pack on to the DART Suture Passer (Figure 7).



Figure 7

4. Wind the suture around the DART Suture Passer posts. Ensure that the suture is taut (Figure 8).



Figure 8

5. Place the suture passer tip into the FDL tunnel and advance the tip as proximally as possible to obtain the maximal hold on the plantar plate. A Cottle Elevator can also be placed just dorsal to the plantar plate to provide clearance from the metatarsal head.

6. Hold the DART Suture Passer in its place, fully depress the spring-loaded needle, then slowly release it to engage the suture (Figure 9).

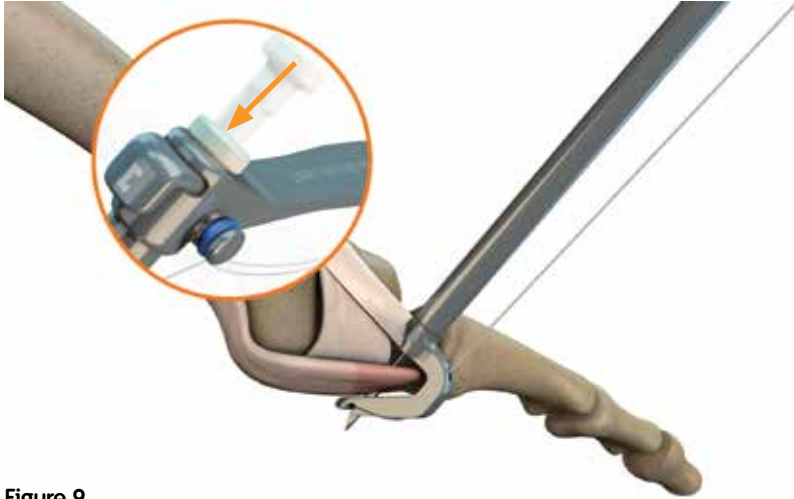


Figure 9

7. Unwind the sutures from the suture passer posts. This will allow the needle to retract while retrieving a suture loop.
8. Retract the suture passer/needle assembly from the surgical site with a gentle rocking motion to expose the suture loops.  
**Note:** Do not remove the needle from the suture passer at this time.
9. Slightly depress the needle to release the suture loop from the needle tip (Figure 10). Grasp the loop of the suture. Remove the suture passer/needle assembly from the joint space.



Figure 10



10. Pass the free ends of the suture through the loop to create a double girth stitch (Figure 11).

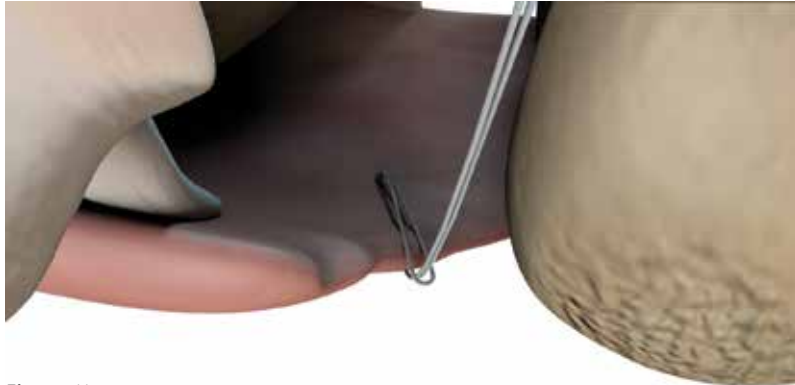


Figure 11

11. Identify the collateral ligament and insert the prong of the DART Suture Passer intra-articularly into the gutter of the joint. Aim the suture passer outward toward the proximal aspect of the collateral ligament.
12. Repeat steps 2–10 with the second ULTRABRAID<sup>®</sup> 2-0 Suture (different color) on the collateral ligament (Figure 12).

**Note:** If additional sutures are needed, ULTRABRAID 2-0 sutures with needles and without needles are available. Refer to the “Ordering Information” section of this document.

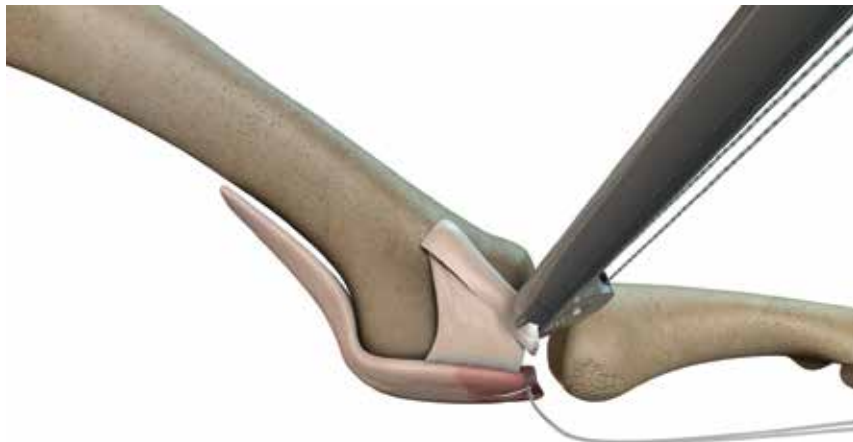
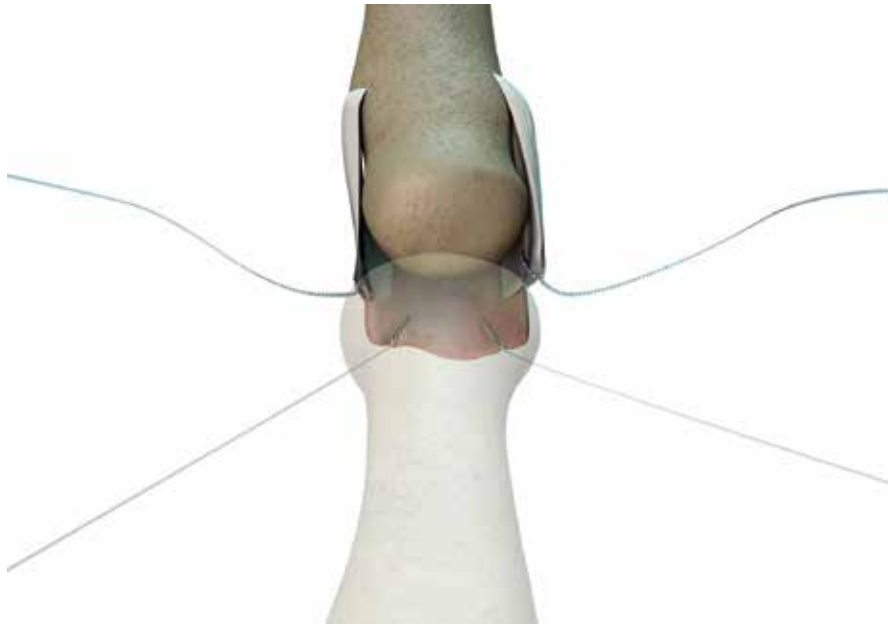


Figure 12: Place the suture in the collateral ligament

13. Perform steps 2–12 to place each suture on the medial and lateral aspects of the plantar plate and both collateral ligaments (4 sutures total) (Figure 13).



**Figure 13**

14. Remove the distractor and K-wires.

## Drill the bone tunnel using the Phalangeal Drill Guide

1. Drill a bone tunnel using the Phalangeal Drill Guide, Short Offset (REF 72204321) and 1.6mm K-wire from the procedure pack. Place the distal tip of the drill guide at the ligament attachment site on the boney rise of the phalanx. Place the curve of the drill guide on the concavity of the phalanx (Figure 14). Place the proximal end of the drill guide 30° – 45° to the sagittal plane.

**Note:** If a freehand tunnel is desired, use the Extra-Articular Drill Guide (REF 72204323).

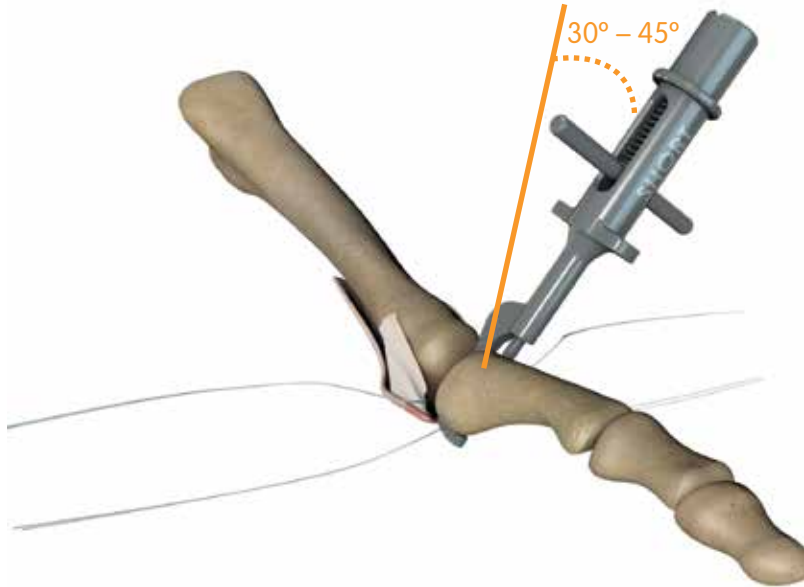


Figure 14: Phalangeal Drill Guide, Short Offset placed at 30 – 45° to the sagittal plane.

2. Drill the K-wire until the proximal end of the depth mark on the K-wire is flush with the proximal end of the drill guide (Figure 15).

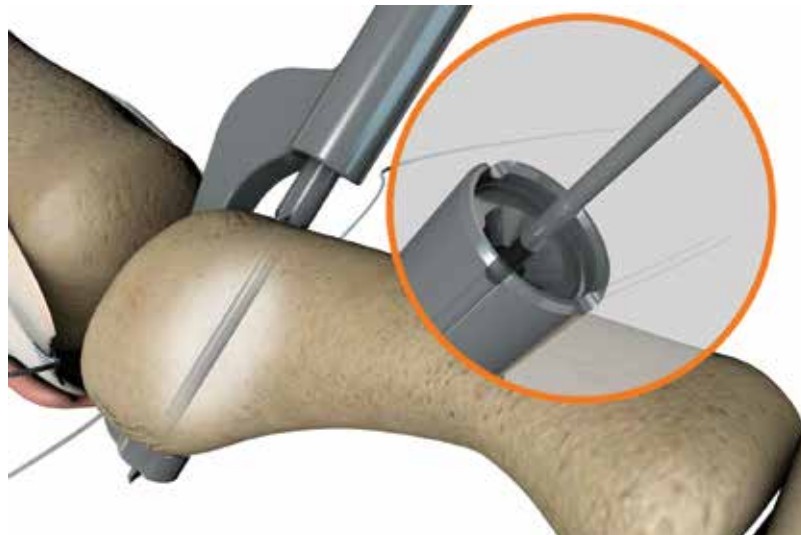


Figure 15

3. Insert the suture shuttle assembly from the Bilateral procedure pack into the phalangeal drill guide until the suture shuttle bottoms out on the proximal face of the drill guide (Figures 16a and 16b).

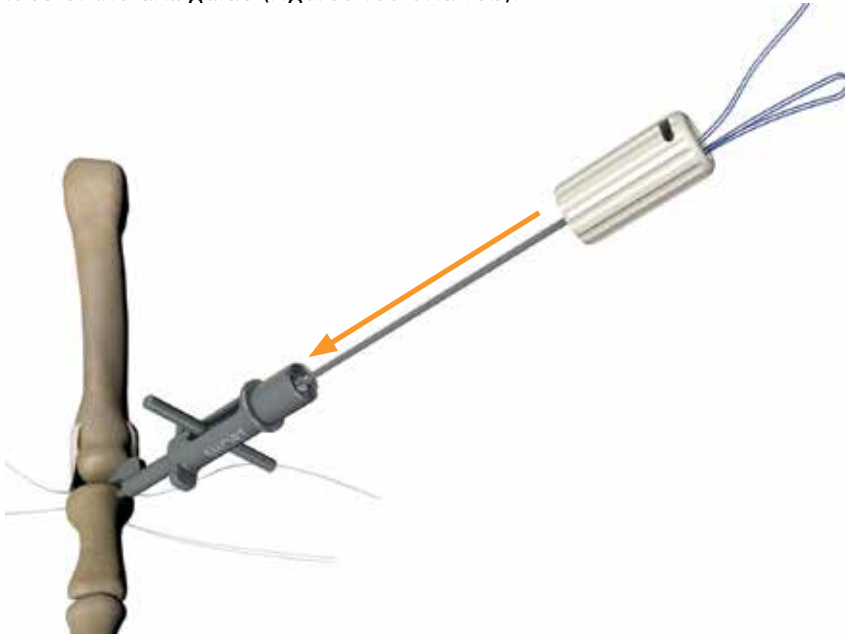


Figure 16a

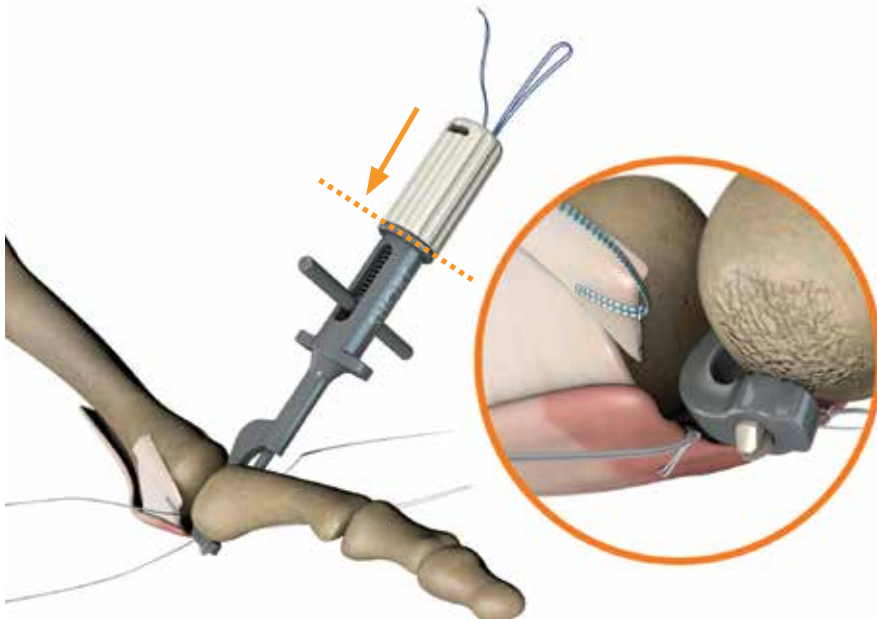


Figure 16b

4. Grasp the suture shuttle handle and remove the suture shuttle assembly, leaving the suture loop in place. Prior to removal, ensure that the sutures' free ends are not through the loop.

5. Place the sutures in the groove on the proximal face of the drill guide (Figure 17).
6. Retract the T-Handle and gently rock the guide out of the joint space. Do not pull the suture when removing the guide (Figure 17).



Figure 17

7. Cut the suture between the distal suture knot and the pledget to free the drill guide. Grasp the suture loop and remove the guide, leaving the suture loop in the tunnel (Figure 18).

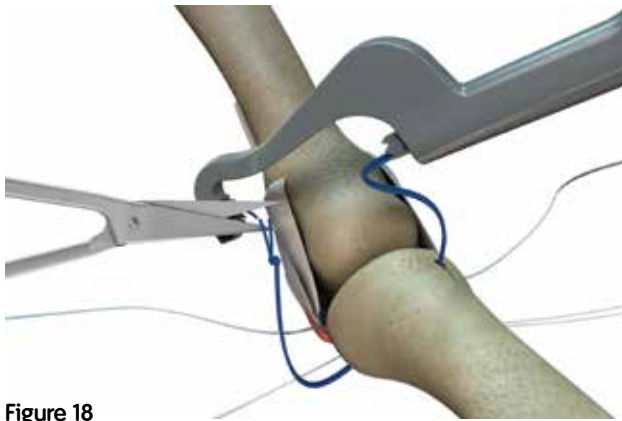


Figure 18

8. Position the Phalangeal Drill Guide, Long Offset contralateral to the first tunnel (Figure 19).

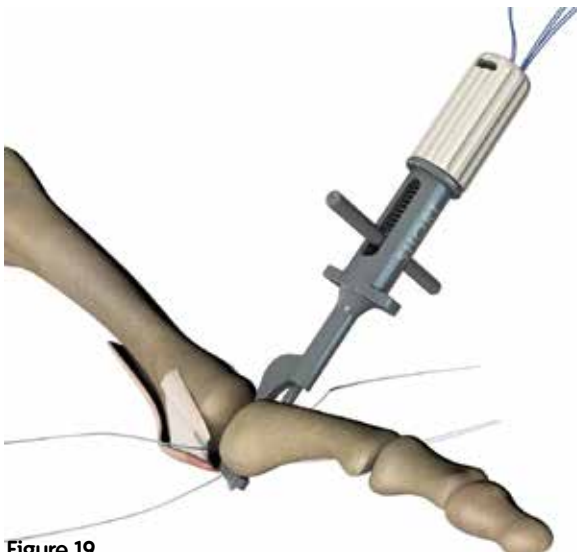


Figure 19

9. Repeat steps 2–7 using the long offset drill guide.
10. Pass the ULTRABRAID® #2-0 Sutures from the lateral plantar plate and collateral ligaments through the suture loop on the lateral plantar side of the tunnel (Figure 20a). Pull the sutures through the bone tunnel and retrieve the sutures on the medial dorsal side of the tunnel (Figures 20b and 20c).

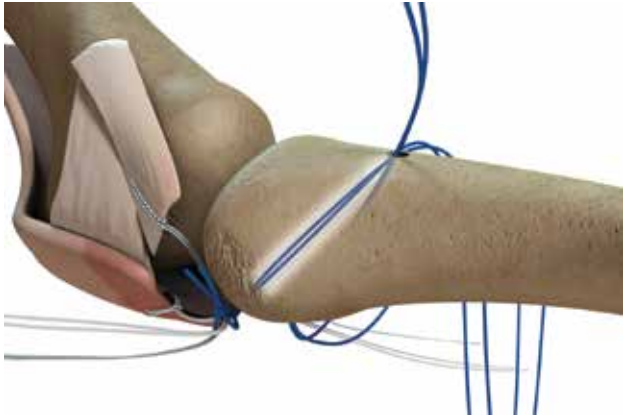


Figure 20a: Pass sutures through the bone tunnel

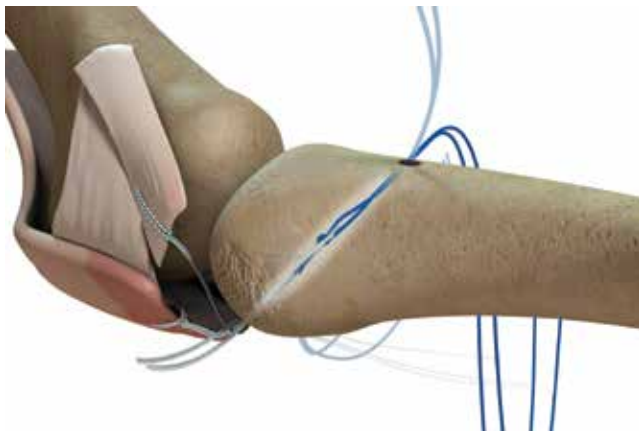


Figure 20b

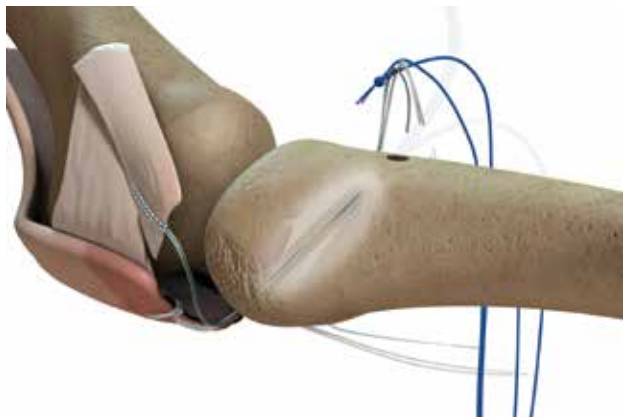


Figure 20c: Retrieve the sutures on the dorsal side

11. Pass the ULTRABRAID® #2-0 sutures from the medial plantar plate and collateral ligaments through the suture loop on the medial plantar side of the tunnel. Pull the sutures through the bone tunnel and retrieve the sutures on the lateral dorsal side of the tunnel (Figure 21).

**Note:** The Nitinol Suture Passer, 5 inches (127mm), can be used to pass the sutures through the bone tunnels.

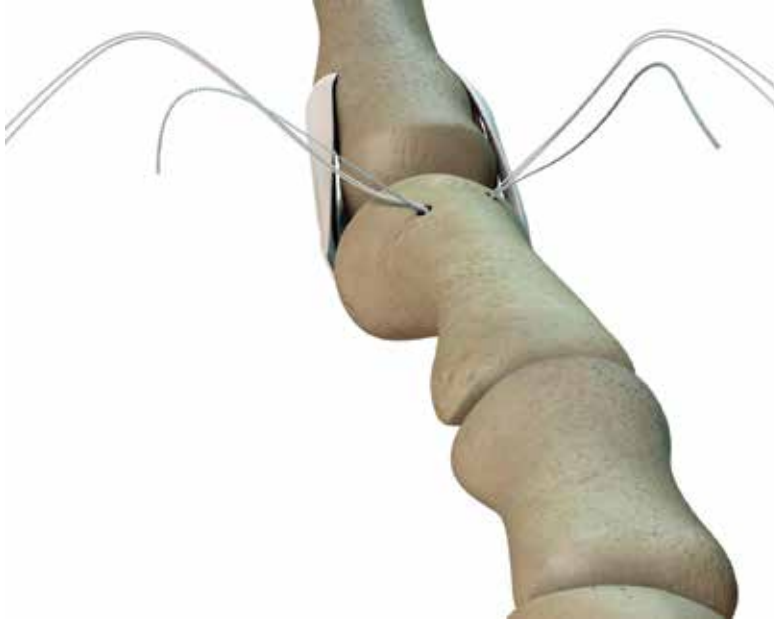
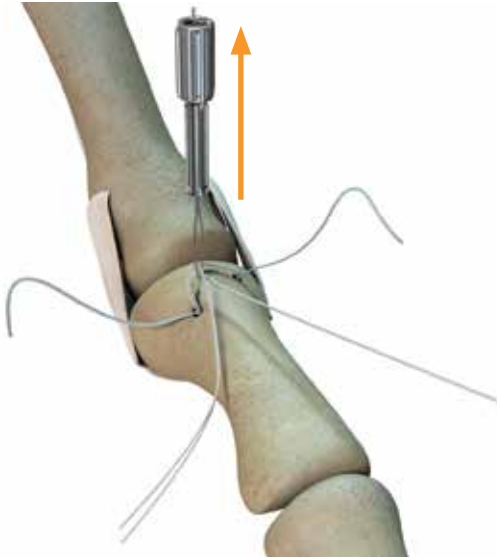


Figure 21: Sutures pulled through the bone tunnels

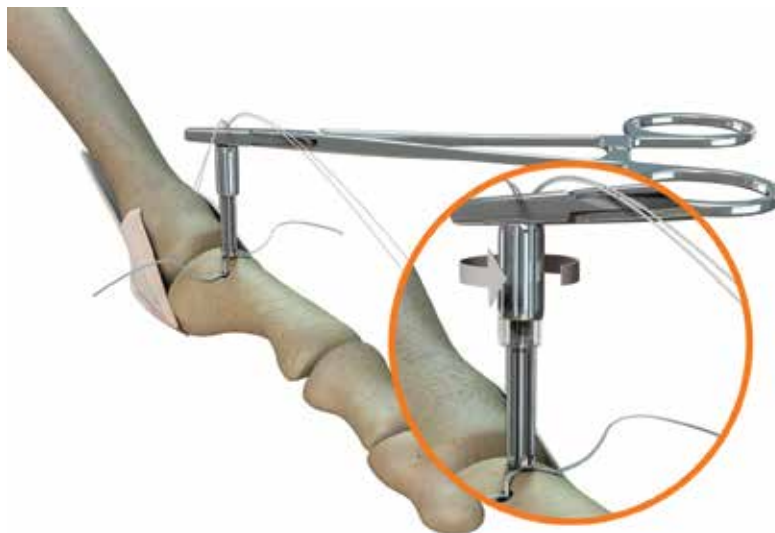
## Tension the construct and complete the repair

1. Separate the plantar plate sutures and the collateral ligament sutures by color. Pass the plantar plate sutures through the suture tensioner (REF 72204324) using the 5 inch (12.7mm) Nitinol Suture Passer from the sterile procedure pack (Figure 22).



**Figure 22**

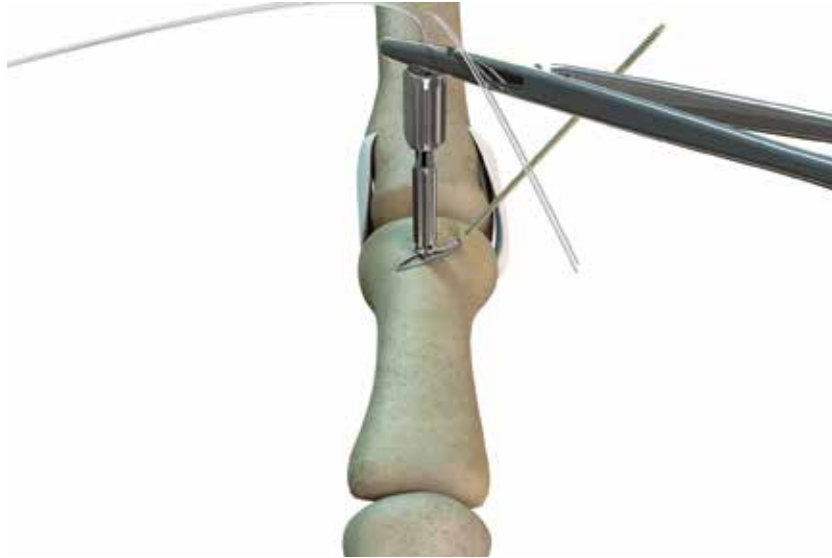
2. Reduce the suture tensioner to its shortest length prior to use. Orient the suture tensioner with the wider section on top when tensioning the sutures.
3. Place the suture tensioner flush against the bone. Tension the sutures until the desired dorsal-plantar stability is achieved.
4. Apply the Snap Clamp (REF 72204336) to the suture directly above the suture tensioner to maintain tension. If additional tension is desired, hold the shaft of the tensioner and rotate the head of the tensioner counterclockwise to further tension the sutures (Figure 23).



**Figure 23**



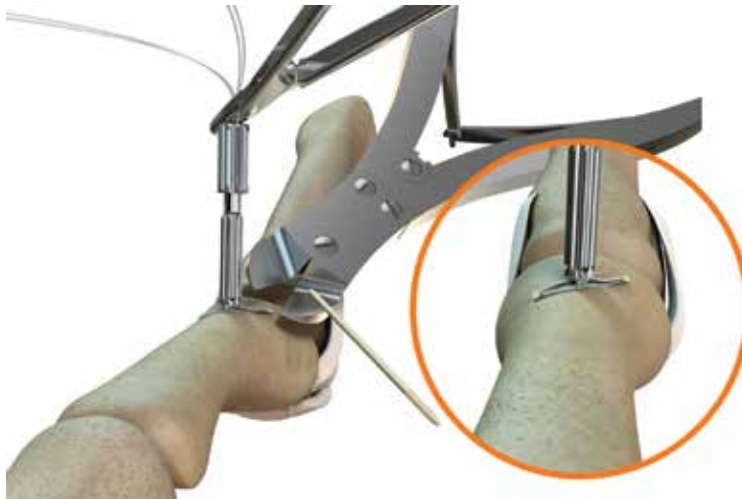5. To adjust mediolateral alignment, pull on the collateral ligament sutures until the desired alignment is achieved. When the desired coronal alignment is achieved, tie the desired fixation knot on the collateral ligaments.
6. Use a K-wire driver to insert one end of the 1.6mm threaded PEEK interference wire into one of the bone tunnels such that all the threads are in the tunnel (Figure 24).



**Figure 24:** Insert the PEEK interference wire into the bone tunnel

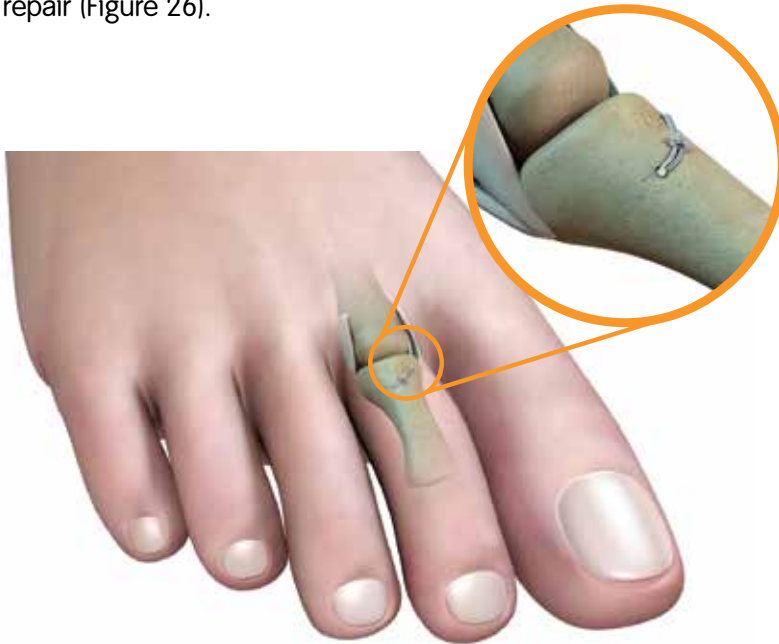7. Once all the interference wire threads are in the tunnel, cut the PEEK interference wire flush with the bone.
8. Insert the interference wire's remaining tip into the remaining bone tunnel. Trim the wire to be flush with the bone (Figure 25).

*CAUTION: Use of excessive force during insertion can cause failure of the threaded PEEK interference wire.*



**Figure 25**

9. Remove the suture tensioner and tie the desired fixation knot to complete the repair (Figure 26).



**Figure 26: Final construct**

## Postoperative care\*

### **Weeks 1–6**

Apply a light bulky dressing, keeping the MTP joint in slight plantar flexion. The patient can do heel weight bearing as tolerated in a postoperative shoe with or without a walking aid. Gentle active ankle and MTP motion is encouraged.

### **Weeks 6–12**

Allow weight bearing as tolerated in a hard-sole shoe. Limit activity to walking only.

### **Weeks 12–16**

Return to low impact sports e.g. bike, pool, hiking, gym. No jumping, turning, twisting or high impact sports.

### **Week 16**

Resume full activities as tolerated.

\* The views and opinions expressed for postoperative care are solely those of the surgeon(s) and do not reflect the views of Smith & Nephew, Inc. In no event shall Smith & Nephew, Inc. be liable for any damages whatsoever (including, without limitation, damages for loss of business profits, business interruption, loss of business information, or other pecuniary loss) arising out of the use of or inability to use the expressed views.

## Notes on Plantar Plate Access

- In cases where the plantar plate is proximally recessed under the metatarsal head and difficult to access with the DART Suture Passer, use a small skin hook to capture the plantar plate and distract it distally.
- If this is insufficient, release the proximal attachment of the plantar plate to the metatarsal head using an elevator to allow sufficient distal mobilization.
- If these two actions do not provide sufficient access to the plantar plate, or in a case of severe longstanding dislocation, especially when the metatarsus is longer than adjacent ones, a metatarsal neck osteotomy may be required before or after plantar plate release.

1. Use the HAT-TRICK® Osteotomy Guide to osteotomize the metatarsal head so that it can be temporarily displaced proximally.

**Note:** For this step, use the proximal two 1.1mm K-wires (REF 71101413) to fix the HAT-TRICK Osteotomy Guide to the metatarsal shaft while aligning the distal end of the guide with the metatarsal head. There is no need to place the distal K-wires.

2. Make a single saw cut for the minimum 1mm shortening. If additional shortening is desired, use the appropriate size spacer plate to make a second cut. This step will provide a full view of the plantar plate and will be helpful for the minority of cases where plantar plate tears are more proximal or are longitudinal.
3. After stitching the plantar plate, reduce and fix the distal fragment with a screw, then continue the ligament reattachment as preferred.

# Ordering Information

To order the items used in these techniques, call +1 800 238 7538 in the US or contact an authorized Smith & Nephew representative. Prior to performing these techniques, consult the Instructions for Use documentation provided with individual components – including indications, contraindications, warnings, cautions and instructions.

## HAT-TRICK<sup>®</sup> MTP Repair Instrument Set

REF 72204305

Cat. No	Description
72204320	HAT-TRICK DART Suture Passer
72204321	HAT-TRICK Phalangeal Drill Guide, Short Offset
72204322	HAT-TRICK Phalangeal Drill Guide, Long Offset
72204323	HAT-TRICK Extra Articular Drill Guide
72204324	HAT-TRICK Suture Tensioner
72204337	HAT-TRICK Modular Handle
72204338	HAT-TRICK Driver Shaft, Cannulated Screw
72204339	HAT-TRICK TAP, Cannulated Screw
72204346	Cottle Elevator
72204349	Rasp, Double Ended
72204347	Small Joint Pin Distractor 1.1mm and 1.6mm Pin
72204348	Trigger Retractor
72204336	Snap Clamp
72204351	HAT-TRICK MTP Repair and Osteotomy Sterilization Tray

## HAT-TRICK Bilateral Sterile Procedure Pack

REF 72204326

Qty	Description
1 ea	HAT-TRICK PEEK Interference Wire, 1.6mm x 76mm
2 ea	HAT-TRICK DART Suture Passer Needle
2 ea	HAT-TRICK Suture Shuttle
1 ea	HAT-TRICK Nitinol Suture Passer, 5 inches
4 ea	1.6mm Drill Tip Wire, 150mm
2 ea	ULTRABRAID <sup>®</sup> 2-0, Co-braid White/Blue Suture, 24 inches
2 ea	ULTRABRAID 2-0 White Suture, 24 inches

## ULTRABRAID 2-0 Sutures (10 Pack)

Cat. No	Description
72204329	(10) ULTRABRAID 2-0 White suture, 24 inches
72204330	(10) ULTRABRAID 2-0 Co-braid White/Blue suture, 24 inches

# Notes

# Notes

# Notes

## References

1. Hofstaetter SG, Hofstaetter, JG, Petroutsas, JA, Gruber F, Ritschl P, Trinka HJ. The Weil Osteotomy: A Seven-Year Follow-up. J Bone Joint Surg (Br) 2005;87-B:1507-11.
2. Beech I, Rees S, Tagoe M. A Retrospective Review of the Weil Metatarsal Osteotomy for Lesser Metatarsal Deformities: An Intermediate Follow-up Analysis. J Foot Ankle Surg 2005; 44(5):358-364.
3. Highlander P, VonHerbulis E, Gonzalez A, Britt J, Buchman J. Complications of the Weil Osteotomy. Foot Ankle Spec 2011; 4: 165-170.
4. Myerson M, Jung HG. The Role of Toe Flexor-to-Extensor Transfer in Correcting Metatarsophalangeal Joint Instability of the Second Toe. Foot Ankle Int 2005; 26: 675-679.
5. Internal Testing.

**Smith & Nephew, Inc.**  
150 Minuteman Road  
Andover, MA 01810  
USA

[www.smith-nephew.com](http://www.smith-nephew.com)

Telephone: 1-901-396-2121  
Information: 1-800-821-5700  
Orders and Inquiries: 1-800-238-7538

©2014 Smith & Nephew, Inc.  
All rights reserved.  
02487 V3 10/14