

Case studies

ECHELON[◇] Revision Hip System

Revision hip surgery poses many challenges to the orthopaedic surgeon. From implant fixation to addressing bone loss, a total hip system is needed that can accommodate these special circumstances.

The ECHELON Revision Hip System is one of the most comprehensive collections of revision femoral implants ever assembled. Updated and innovative designs build on proven clinical concepts to provide a simple and flexible solution to difficult problems. Porous and cemented femoral components are available to address varying indications. Calcar build ups address bone loss issues usually found in revision situations.

A straightforward surgical technique is applied with easy-to-use instruments that provide accurate and reproducible results. Sharp, precise reamers are used prior to precision ground broaches for careful preparation of the femoral canal.

A series of cases are presented demonstrating how the ECHELON Revision Hip System can be used to address a variety of difficult clinical challenges.

Porous implants

Porous coating

ROUGHCOAT® porous coating increases the friction between the implant and bone, improving implant stability and providing a porous surface for bone ingrowth.

Driving platform

The ECHELON® implants feature a threaded driving platform with an elliptical slot for rotational and axial implant control during insertion.

Neck geometry

Circulotrapezoidal neck provides increased range of motion compared to a circular neck of the same strength.

Collar options

A standard collar and two calcar platforms are available to match the implant to the proximal defect.



190mm straight

Shoulder relief

The lateral shoulder is rounded to minimize the risk of fracturing the greater trochanter during stem insertion.

Lateral proximal flare

The ECHELON stem has a 3° proximal anterior/posterior flare to improve proximal fill, without preventing implant seating.

Distal flutes

The ECHELON system offers distal flutes to increase rotational stability.

Distal slot

The distal slot eases stem insertion, reduces the risk of fracture, and reduces distal stem stiffness.

Distal bullet tip

The bullet tip reduces the stress between the distal implant tip and the bone to minimize end of stem thigh pain.

Size range

ECHELON porous stems are offered in 1mm increments to minimize bone removal and provide optimum canal fill.



260mm bowed

Cemented implants

Double taper proximal geometry

Limits shear stresses and promotes compressive stress transfer between the cement and implant.

Proximal A/P groove

Increases rotational stability without increasing cement stresses.

Trapezoidal distal cross section

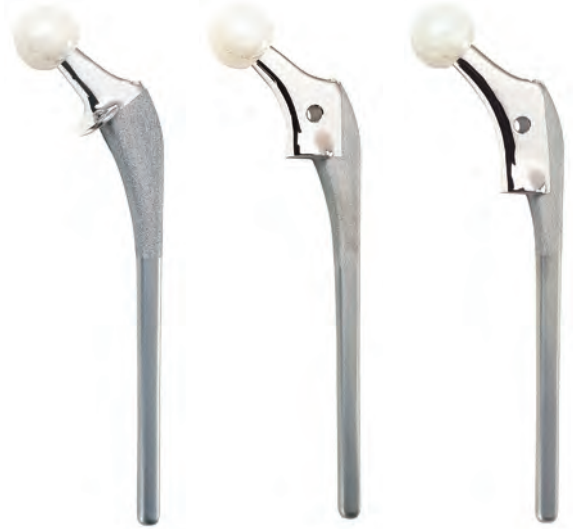Improves resistance to rotation.

Neck geometry

Circulotrapezoidal neck provides increased range of motion compared to a circular neck of the same strength.

Collar options

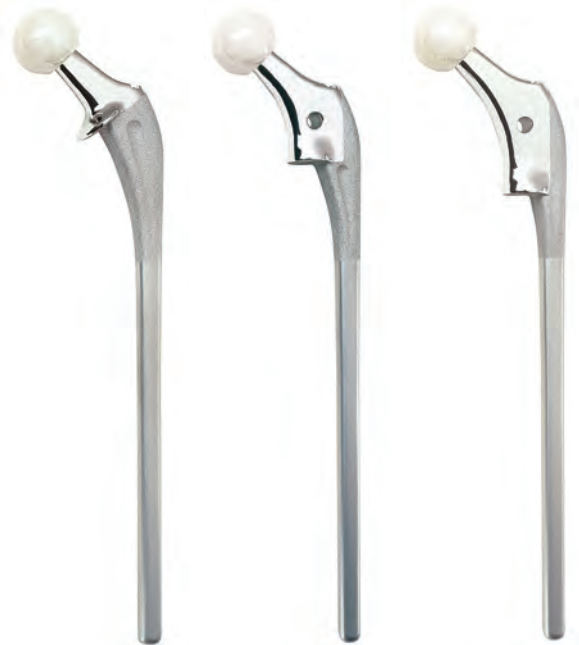A standard collar and two calcar platforms are available to match the implant to the proximal defect.



175mm

The ECHELON implants are made from Cobalt Chromium material.

An optimized 12/14 taper is used to lock the modular head to the stem.



225mm

Case studies

Case study 1

Female, age 74

Pre op condition

- Aseptic loosening of femoral prosthesis

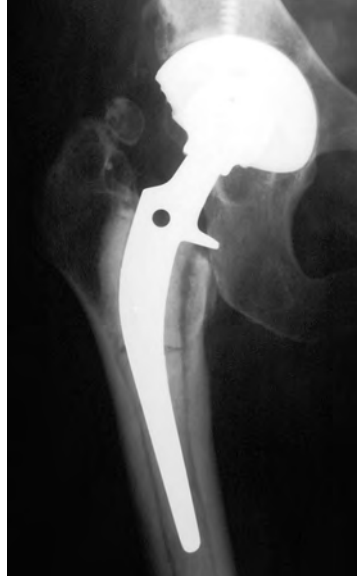Solution

- Porous straight stem with standard collar

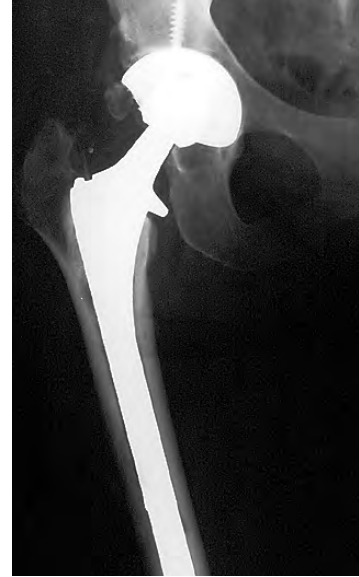Post-op condition

- Joint function restored
- Good fixation of femoral implant

Case submitted by Dr Michael Lynch



Pre op



4 months



Case study 2

Male, age 69

Pre op condition

- Failed cemented total hip

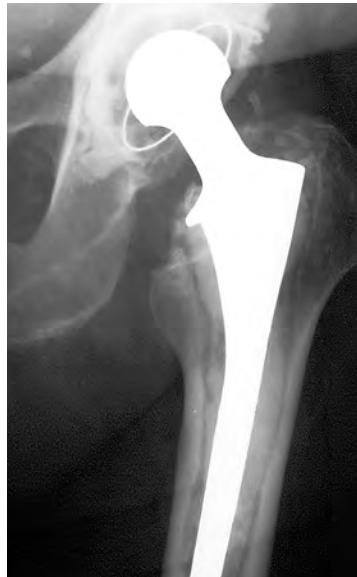Solution

- Porous straight stem with standard collar
- INTERFIT[®] cup

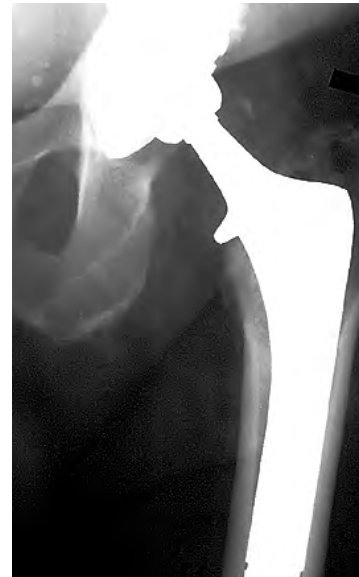Post-op condition

- No thigh pain even with large diameter stem

Case submitted by Dr James Harkess



Pre op



Post-op



Case study 3
Female, age 46

Pre op condition

- Loose, painful stem
- No bone ingrowth upon retrieval

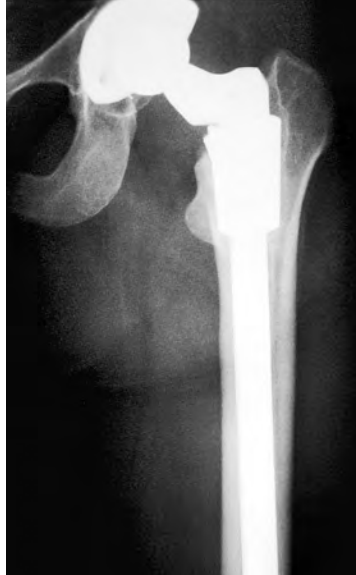Solution

- Porous straight stem with standard collar

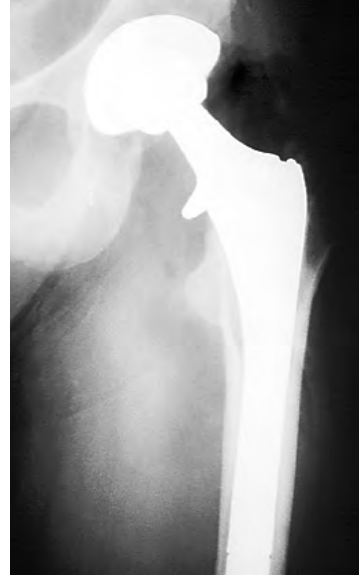Post-op condition

- Good clinical outcome
- No cortical thinning
- No thigh pain

Case submitted by Dr Robert Barrack



Pre op



Post-op



Case study 4
Male, age 78

Pre op condition

- THA following post-traumatic AVN in 1975
- Socket revised with high hip center in 1991
- Broken acetabular screw
- Massive acetabular osteolysis

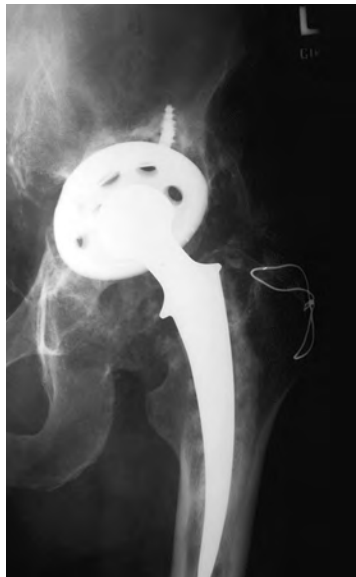Solution

- Porous straight stem with standard collar
- CONTOUR® Reconstruction Ring

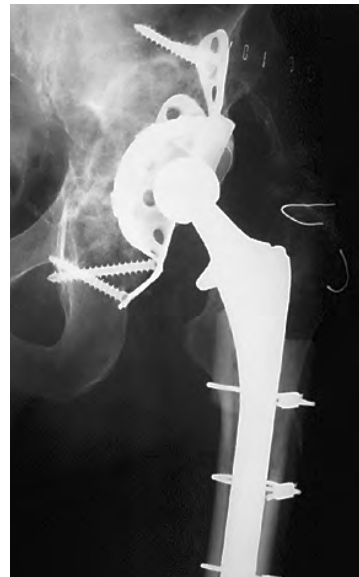Post-op condition

- Acetabular osteolytic lesion filled with cancellous allograft
- Strut over distal canal perforation and well positioned revision total hip
- Some leg length restored and more normal femoral offset restored

Case submitted by Dr Richard Sanders



Pre op



Post-op



Case studies

Case study 5

Male, age 53

Pre op condition

- Failed cemented broken hip
- Hip nearly ankylosed
- Loss of calcar to osteolysis

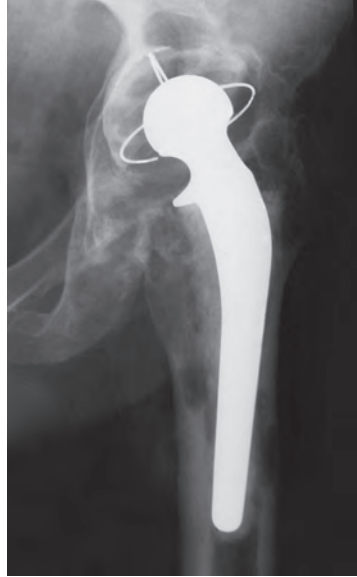Solution

- Porous straight stem with +15mm calcar build up
- INTERFIT[®] cup

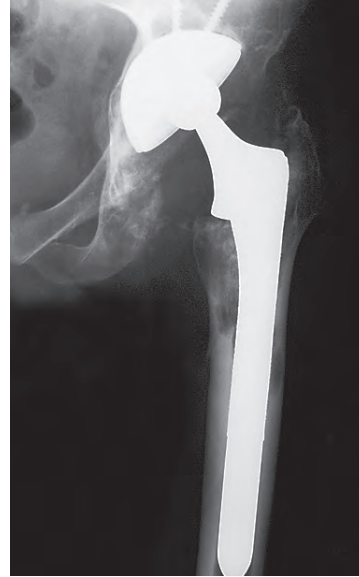Post-op condition

- Leg length and offset restored with significant improvement in motion

Case submitted by Dr James Harkess



Pre op



Post-op



Case study 6

Male, age 44

Pre op condition

- Implant ingrown but severe thigh pain

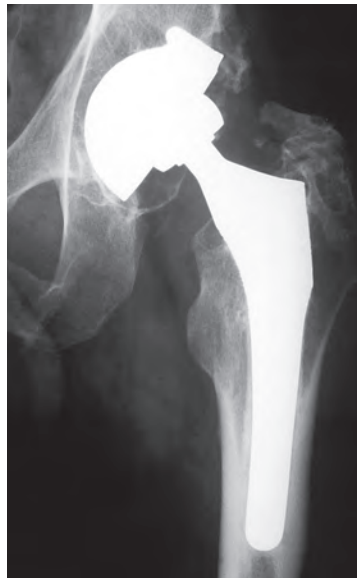Solution

- Porous straight stem with +15mm calcar build up

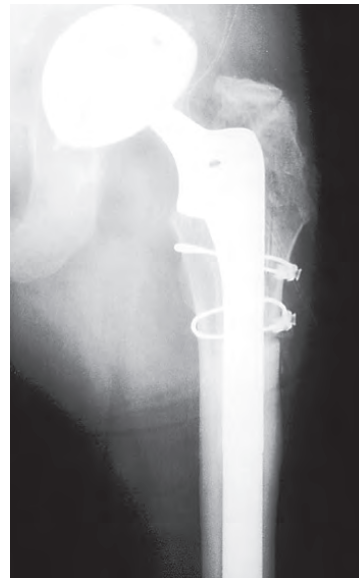
Post-op condition

- No limp
- Slight activity-related thigh pain which resolved by 1 year post-op

Case submitted by Dr Robert Barrack



Pre op



Post-op



Case study 7
Female, age 87

Pre op condition

- Pain, decreased function
- 18 years after first THR
- Significant peri-prosthetic osteolysis of the femur with migration of the acetabular component and subsidence of the femoral implant

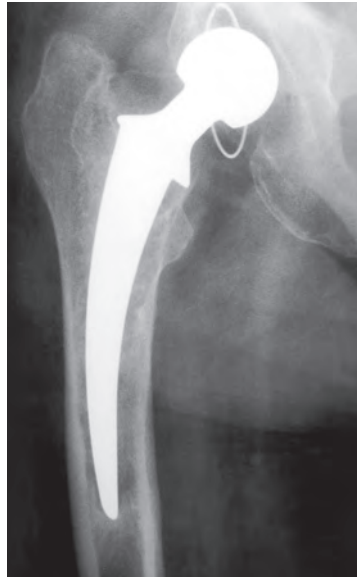Solution

- Porous straight stem with +15 mm calcar build up
- INTERFIT® cup

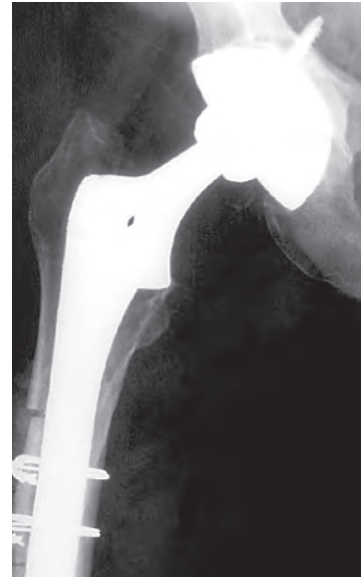Post-op condition

- Substantially improved
- Limb length restored
- Distal cortical window used to remove the distal cement
- Morselized allograft was used to reconstruct the acetabulum

Case submitted by Dr James Waddell



Pre op



3 months



Case study 8
Male, age 53

Pre op condition

- Hemi-arthroplasty with aseptic loosening

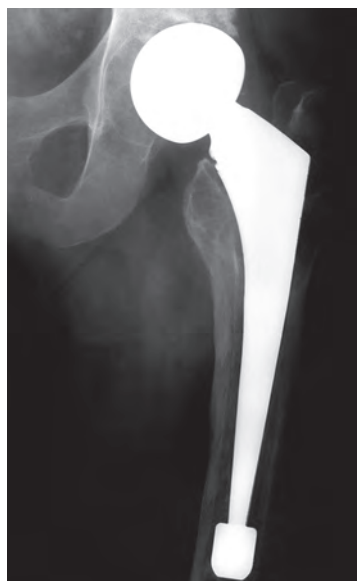Solution

- Porous bowed stem with standard collar
- REFLECTION® cup

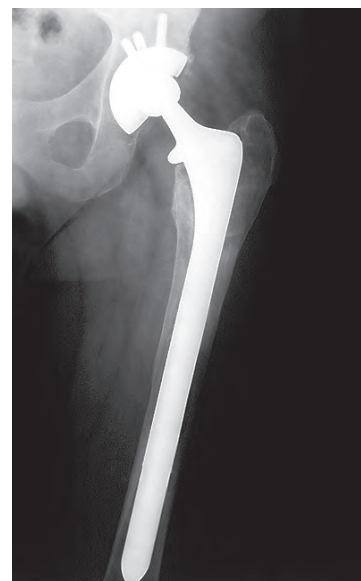Post-op condition

- Good clinical outcome
- No complications

Case submitted by Dr John McCutchen



Pre op



Post-op



Case studies

Case study 9

Female, age 45

Pre op condition

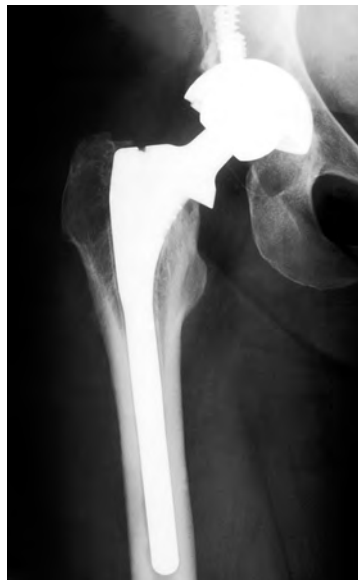- Thigh pain
- Minimally ingrown patch porous coated stem
- Massive pelvic lysis

Solution

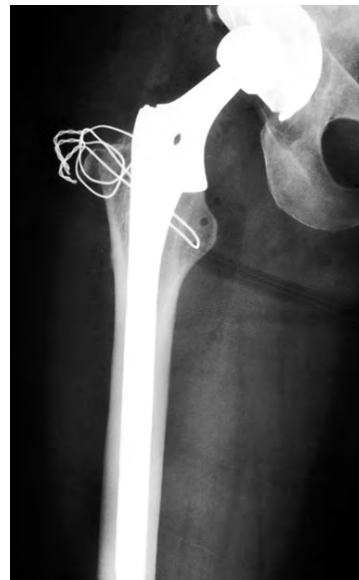- Porous bowed stem with +15 mm calcar build up

Post-op condition

- Good clinical outcome
- Implant coronal slot closed
- No thigh pain



Pre op



4 months



Case submitted by Dr Robert Barrack

Case study 10

Female, age 64

Pre op condition

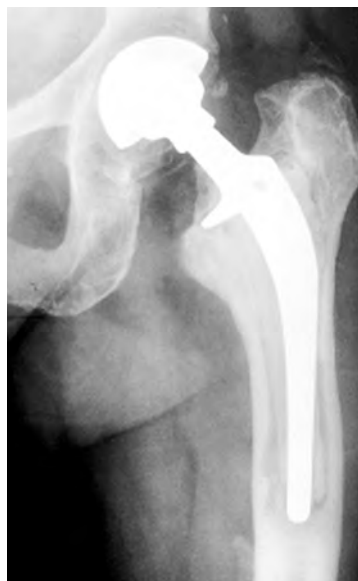- Debonded stem
- Well-fixed cement

Solution

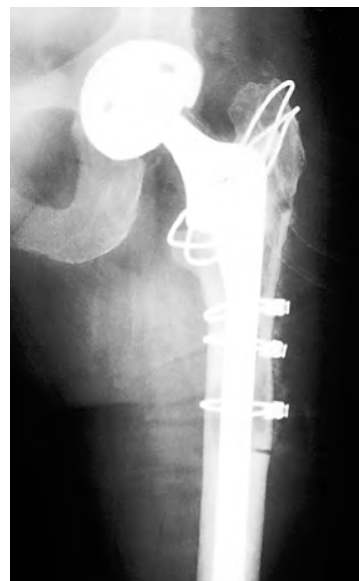- Porous Bowed Stem with +15mm calcar build up
- Extended trochanteric osteotomy used to remove cement

Post-op condition

- Fully ambulatory at 1.5 years with no assistive devices



Pre op



Post-op



Case submitted by Dr Robert Barrack

Case study 11
Female, age 58

Pre op condition

- Gross loosening of stem with thin lateral cortex

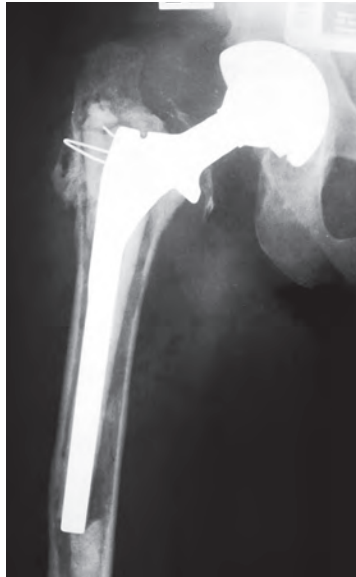Solution

- Porous Bowed Stem with +15 mm calcar build up
- Extended osteotomy performed and reinforced with strut graft

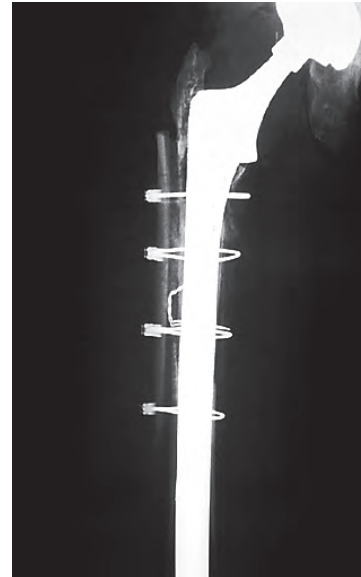
Post-op condition

- Good ambulation at 1 year
- Cane only on long walks

Case submitted by Dr. Robert Barrack



Pre op



Post-op



Case study 12
Male, age 34

Pre op condition

- Failed revision total hip with marked subsidence
- 4cm of limb shortenting
- Retroversion of acetabular component
- Marked Trendelenburg limp

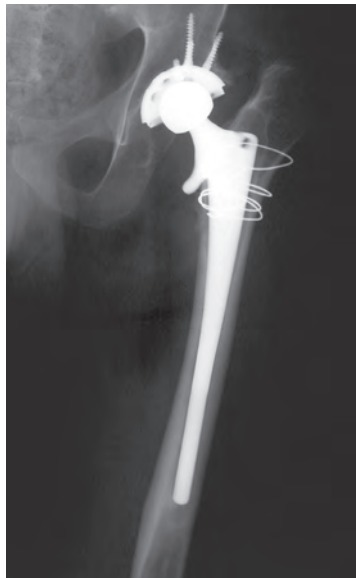
Solution

- Porous Bowed Stem with +30mm calcar build up
- INTERFIT[®] cup

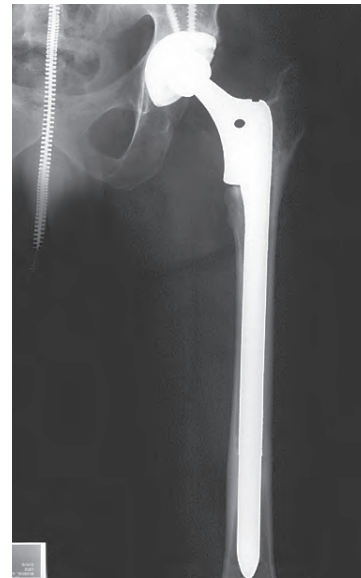
Post-op condition

- Leg length restored
- Walks without support
- No limp

Case submitted by Dr. James Harkess



Pre op



Post-op



Case studies

Case study 13

Female, age 84

Pre op condition

- Revision of hybrid hip

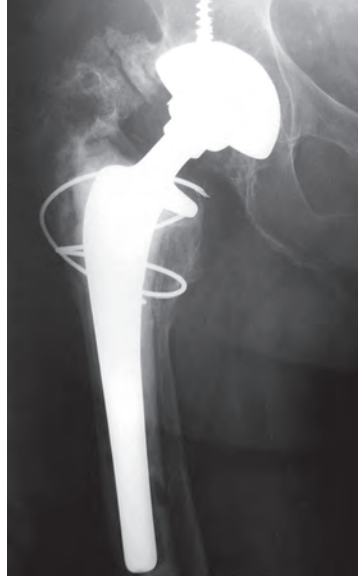Solution

- Cemented, 175mm stem with standard collar
- INTERFIT[®] cup

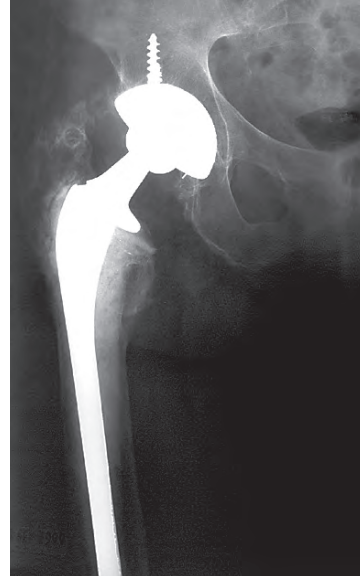Post-op condition

- Restoration of joint function

Case submitted by Dr. John McCutchen



Pre op



Post-op



Case study 14

Female, age 74

Pre op condition

- Revision of precoat stem due to aseptic loosening

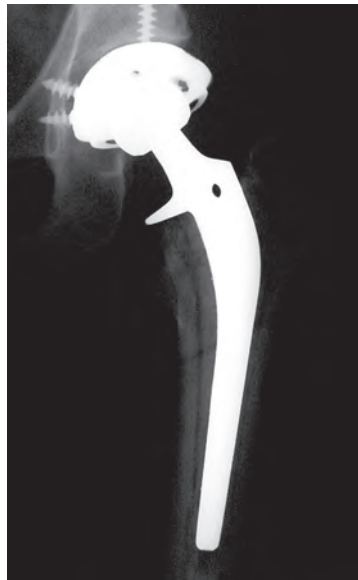Solution

- Cemented, 225mm stem with standard collar

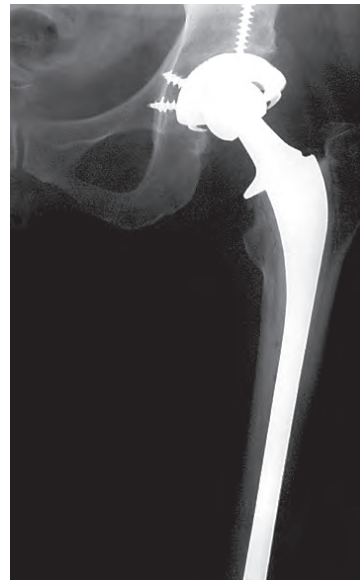Post-op condition

- Good postoperative outcome with no complications

Case submitted by Dr John McCutchen



Pre op



Post-op



Case study 15
Female, age 79

Pre op condition

- 17 years post-op primary THA
- Pain with ambulation for 3 years

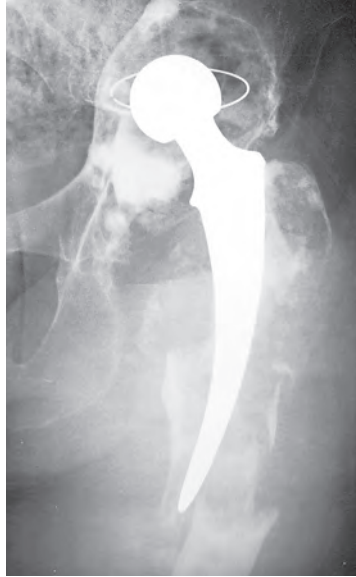Solution

- Cemented, 225mm stem with standard collar
- CONTOUR[®] Reconstruction Ring

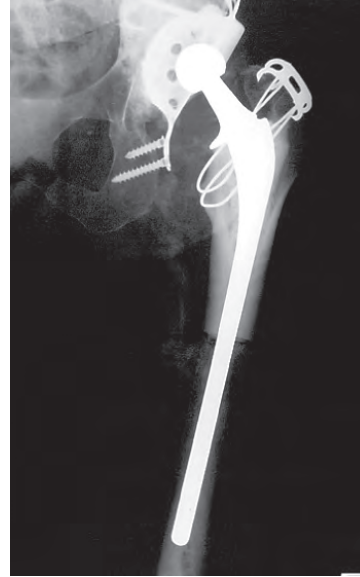Post-op condition

- Proximal femoral allograft securely fixed with implant
- Good ambulation

Case submitted by Dr. James Guyton



Pre op



6 months



Smith & Nephew, Inc.
7135 Goodlett Farms Parkway
Cordova, TN 38016
USA

www.smith-nephew.com

Telephone: 1-901-396-2121
Information: 1-800-821-5700
Orders and Inquiries: 1-800-238-7538

°Trademark of Smith & Nephew. Reg. US Pat. & TM Off.

©2011 Smith & Nephew, Inc.
All rights reserved.
71380632 11/11